

HAND SURGERY

Q U A R T E R L Y

Winter
2011

- 2 From the Editor's Desk
AAHS Calendar of Meetings
- 3 Hand Therapist & Affiliates' Corner
- 5 Coding Corner
- 6 Around the Hand Table: Treatment of Dupuytren's Disease
- 11 Hand Therapy Techniques for Stages of Dupuytren's
- 15 Hand Therapy Profile: Charleen Stennett, OTR/L, CHT
- 17 2011 Annual Meeting Program at a Glance
- 20 Mentor Program

MESSAGE FROM THE PRESIDENT

Welcome to Cancun!

Hopefully the weather has cooperated and we are enjoying tropical breezes and warm sands. One of the advantages of the of the AAHS meeting is that it balances a superb educational program (this year masterminded by Jesse Jupiter and Sue Michlovitz) and time for socializing and relaxing with colleagues. The importance of such time spent in conversation and shared experiences highlights the theme of the Cancun meeting: collegiality. We have a number of Latin and South American colleagues attending and we acknowledge their friendship and importance in the dialog of hand surgery.

Hand surgery is a small world. That size offers us the ability to personally discuss difficult cases and share concerns over patient care, the business of hand surgery, and other pertinent issues. The AAHS meeting provides the perfect forum for such conversations. So take the opportunity to share a margarita and your thoughts.

Also take advantage of the offshore meeting site to explore the Mayan Riviera. While Cancun is the heart of the meeting, an afternoon boat ride to Isla Mujeres is a worthwhile excursion. In Mayan times, the island served as the sanctuary for the goddess Ixchel, the Goddess of fertility, medicine, happiness and the moon. In 1517, when the Spanish expedition under Cordova landed, they

found many female shaped idols representing the goddess Ixchel, thus Isla Mujeres got its name, the island of the women.

For the more adventuresome, rent a car or take a tour to Playa del Carmen, the bustling city of the Riviera Maya. Then onward to the Mayan ruins at Tulum and Coba. At the height of the Mayan civilization, Coba had over 50,000 inhabitants. Amble down a mile long path to Nohoch Mul, which at 140 feet is the tallest pyramid on the Yucatan. It's the only one left in Mexico that you can still climb.



A. LEE OSTERMAN,
MD, FACS

So despite the heat and the incline, that's what you do. At the top you'll see the altar—likely the site of human sacrifice—and a view of verdant jungle as far as the eye can see, patrolled from above by awooping hawks and quetzals. In that serenity you can contemplate and digest the teachings of the IC you attended or the musings of the adventurer, Aron Ralston, our guest speaker.

Finally, cool off with a swim in a cenote. The entire Yucatan is a honeycomb of underground rivers and caverns called cenotes. The most profound is the legendary Dos Ojos Cenote. A local guide equips you with snorkel, mask, and flippers and leads you into the chilly, crystal clear water. Water temperature

continued on page 3



Nohoch Mul is the tallest pyramid on the Yucatan.



www.handsurgery.org
900 Cummings Center
Suite 221U
Beverly, MA 01915

The Rules of Engagement

Scott Kozin served as the president of the AAHS from 2008-2009. In the year prior, he had approached me to serve as a representative from the AAHS to the AAOS (American Academy of Orthopaedic Surgery). Prior to that, I had very little involvement in "organized medicine." I had attended the meetings, obtained my CME, made a few presentations, but that was about all. This was my first opportunity to see how these organizations functioned to serve their members.

The AAOS has several boards that guide their society. One of these had been recently reorganized into the Board of Specialty Societies (BOS). Each specialty society has a set number of representatives to that board who then make recommendations about how the AAOS can better serve and work with the various specialty societies. This was the role I was given by Scott in 2007. Apparently the structure that had been in place prior to my joining the BOS was ineffective and the BOS was an attempt by the AAOS to better interact with the various specialty societies. As a result, the leaders of this group were charged with an openness and flexibility to work with the specialty societies toward a more productive relationship.

As a resident and as a young attending I had looked at the AAOS, the ASSH and the AAHS as organizations that I would join. They were run by people whose names I had read in journals and texts, or after whom a procedure or piece of surgical equipment had been named. They were, I thought, designed to give me the information I would need to develop in my practice as a hand and upper-

extremity surgeon.

At my first fall meeting of the BOS, however, I realized that these organizations are dynamic and in constant need of innovation and interested volunteers. For the first time I recognized that these were not associations that I would join, but rather that they were my friends and colleagues associated toward common goals. The AAOS was not a society that was telling me what to do, but instead was asking me what should be done. It was really very enlightening to think of the AAHS and the AAOS as my organizations working for me.

Since that time, I have been elected to serve as the junior-member-at-large on the board of the AAHS. At my first board meeting I was asked to take over as editor of this newsletter. This demonstrates, I think, the willingness of the AAHS to have member input and involvement. It also demonstrates the need for more member participation. There are countless opportunities to get involved.

So, I encourage each member of the AAHS to become engaged.

Becoming involved in our association allows you to mold it to your needs. One of the most difficult tasks a professional society faces is accurately assessing its member's needs and responding to them. There is no better way to do this than to have greater member involvement. So plan to attend the business meeting in Cancun or look to join a committee.

Finally, as I assume the role of the editor of this newsletter, I will encourage member participation here as well. I encourage any feedback on the form or content of our newsletter. I also encourage contributions or suggestions for topics by our members. If there are members who wish to become involved in a routine column or to participate in a round-table discussion, I would invite your input. It is your newsletter and your association. Become engaged in order to make them a success! **H**



THOMAS HUGHES, MD

AAHS Calendar

2011

January 12-15, 2011
AAHS 41st Annual Meeting
Ritz Carlton Cancun
Cancun, Mexico

February 16-20, 2011
AAOS Annual Meeting
San Diego, CA

September 8-10, 2011
ASSH Annual Meeting
Las Vegas, NV

September 23-28, 2011
ASPS Annual Meeting
Denver, CO

2012

January 11-14, 2012
AAHS 42nd Annual Meeting
Red Rock Casino Resort & Spa
Las Vegas, NV

2013

January 9-12, 2013
AAHS 43rd Annual Meeting
Naples Grande Resort & Club
Naples, FL

2014

January 8-11, 2014
AAHS 44th Annual Meeting
Grand Hyatt Kauai Resort & Spa
Kauai, HI

For information contact:
AAHS Central Office at 978-927-8330
or www.handsurgery.org

Hand
Surgery
Quarterly

.....

Winter
2011

2

continued from page 1

is 77° Fahrenheit throughout the year and the maximum depth is approximately 30 feet. The water is exceptionally clear as a result of being rainwater filtered through limestone; for an hour you are on another planet. Renewed and refreshed, you are ready for the Friday evening gala salsa party.

Cancun and its environs are an exciting venue in keeping with the AAHS mission of providing a special personal, social, and educational experience for our members. As President this year, I have been lucky to have a dynamic board that has worked diligently to augment the Associations' education, research, and service goals, while maintaining our fiscal solvency in these tumultuous economic times. Your association is in good hands. So celebrate the passion that is hand surgery today and in the future. Best wishes for the holidays and a prosperous New Year. **H**

HAND SURGERY QUARTERLY

President

A. Lee Osterman, MD, FACS

Editor

Thomas Hughes, MD

Managing Editor

Anne Behrens

Hand Surgery Quarterly is a publication of The American Association for Hand Surgery and is published strictly for the members of AAHS. This publication is designed as a forum for open discussion and debate among the AAHS membership. Opinions discussed are those of the authors or speakers and are not necessarily the position, posture or stance of the Association.

Copyright ©2010, The American Association for Hand Surgery. All rights reserved. No portion of this newsletter may be printed without express written permission from the publisher, 900 Cummings Center, Suite 221U, Beverly, MA 01915, 978-927-8330.

Let's See the Results!

It is thought that a picture speaks a thousand words. Then it is plausible that a video can tell a whole story. In this time, video technology is all the rage. It is time to get out the video camera and capture our results and innovations in hand therapy rehabilitation.

The invention of the Internet has become an essential tool for evaluators, researchers, and educators. It is used for communication, online data collection, retrieving data and research, online learning, and forum chats. And now with social networking programs such as Facebook and YouTube, the internet is fundamentally altering how people (young and old) consume information, particularly in the form of video content.

It is fascinating to go to a site such as YouTube and search hand rehabilitation or splinting. You see companies advertising products, hand professionals showing off skills or inventions, even hand rehabilitation patients becoming video stars themselves. Hours of videos where our patients are showing functional gains in range of motion and occupation because of the exercises prescribed, the dynamic splint worn, and the therapy used.

Incorporating videos into our presentations is an excellent tool to market new ideas and hand rehabilitation practices. When speaking to a group, video clips can help focus an audience, wake up the audience, and connect with the audience. This is the power of video. A short video clip can illustrate a principle, it can demonstrate how a splint works, it can demonstrate live results in hand function that is being achieved, it allows for testimonials of satisfied patients. Adding video to a slide presenta-

tion allows information to be shared, that offers a personal touch that is not available with still pictures alone.

Using video does not need to be expensive; it can be done with the video mode of a digital camera or a camcorder. Of course willing patient participation and consent is absolutely necessary. Once videos have been taken they can be stored as files on computer hard drives or memory sticks. Most computers are equipped with adequate video editing programs on the operating system. For example on Windows, there is Windows Movie Maker and on Mac there is iMovie. Use these programs to cut out a section of video, split video and/or mash two clips together. To make the use of a video appear seamless in your presentation, save the video clip in a folder and then insert the video clip on a slide within the presentation. (For example power point presentation slides). This is referred to as embedding the video clip into a slide.

Most information sharing outlets are resorting to internet access. Even this newsletter is available online if preferred, rather than receiving a paper copy. Online submissions are being used for journal applications. Why not include video clips along with an online paper submission to capture the intended audience and demonstrate results. Including video clips in our presentations and other educational applications will give audiences clear, concise and QUICK information. **H**



AMANDA HIGGINS,
OT

2011
PHILADELPHIA
13th Annual Hand Surgery Symposium
March 5-7, 2011

dancing with
the
elbowstars

Honored Professors

Mark S. Cohen, MD
A. Lee Dellon, MD, PhD
William B. Geissler, MD
Felix H. Savoie, III, MD

Chairmen

A. Lee Osterman, MD
Randall W. Culp, MD
Neal C. Chen, MD



Sponsored By:



Hand Rehabilitation Foundation



University of Colorado
Denver School of Medicine

Endorsed By:



Supported By:
The Jefferson Health System

Coding and Dupuytren's

It is my privilege to step into a position vacated by Dr. Leon S. Benson, who had provided AAHS *Hand Surgery Quarterly* readers with coding pearls since 2003. Since the focus of this issue is on treatment of Dupuytren's Disease, we will look at related treatment codes in this inaugural edition.

For those of us who utilize more 'traditional' surgical techniques for treatment of Dupuytren's contracture, CPT coding is a relatively straightforward affair. Code 26121 refers to a palmar fasciectomy procedure but is not routinely used to code for functional correction of Dupuytren's deformity. Code 26123 is explicitly used for 'release of a single digit' and includes all surgical techniques for correction including Z-plasties, skin grafting, and proximal interphalangeal joint release. Code 26125 is applied for each additional finger treated and

should be used in conjunction with 26123. Though neuroplasties of the digital nerves would certainly be performed during any corrective surgery for Dupuytren's contracture, code 64702 is essentially bundled into the above CPT codes and cannot be used separately.

When the small finger is involved, the insertion of the abductor digiti quinti muscle is typically identified and excised in order to fully release the digit. In these cases, utilizing code 26593 (release, intrinsic muscles of hand) is reasonable.

Needle aponeurotomy, also called percutaneous needle fasciotomy, is a minimally invasive technique that can be performed in the office. For these cases, code 26040 is used. Open partial fasciotomy is a similar procedure to needle aponeurotomy but is performed in the operating room and employs code 26045.

Effective February 2, 2010, the Food and Drug Administration approved Auxilium Pharmaceutical Inc.'s biologics license application for clostridium histolyticum collagenase (Xiaflex®) to treat

Dupuytren's patients with a palpable cord. According to Medicare, providers could bill for the collagenase injection (code 20550) in addition to the drug (HCPCS code J3590) as of November 15, 2010.

Incidentally, code 20550 is the same one commonly used for corticosteroid injections in treating stenosing tenosynovitis. For accurate payment, these codes should be submitted on the same claim.

Prior to November 15, providers were instructed to bill for code 26989 (unlisted procedure, hands or fingers).

Some insurance providers require very specific documentation of a positive 'table top test,' contracture of at least 30 degrees at the metacarpophalangeal joint or proximal interphalangeal joint, and functional limitations secondary to the flexion deformity. To ensure appropriate payment, it is essential that these findings be spelled out prior to treatment.

Since the use of Xiaflex® requires a manipulation procedure the day after injection, providers can bill code 99213, which pays for evaluation and management of an established patient. Bundled with this fee is manipulation of the finger under local anesthesia or analgesia. Code 29130 can also be utilized for splint application. Most insurance providers will approve Xiaflex® injections if performed by an orthopaedic or plastic surgeon. Up to three injections per cord are typically allowed as indicated at 4 week intervals. Only one cord should be injected at a time. Stay tuned to new developments with Xiaflex® coding, as reimbursement for the procedure under a dedicated CPT code is expected in January, 2012.



EON K. SHIN, MD

Fasciotomy/Fasciectomy Procedure Codes	
26040	Fasciotomy, palmar (eg, Dupuytren's contracture); percutaneous
26045	Fasciotomy, palmar (eg, Dupuytren's contracture); open partial
26121	Fasciectomy, palm only, with or without Z-plasty, other local tissue rearrangement, or skin grafting (includes obtaining graft)
26123	Fasciectomy, partial palmar with release of single digit including proximal interphalangeal joint, with or without Z-plasty, other local tissue rearrangement, or skin grafting (includes obtaining graft)
26125	Same as 26123, each additional digit
26593	Release, intrinsic muscles of hand, each muscle
Clostridial Collagenase Injection Codes	
20550	Injection(s); single tendon sheath, or ligament, aponeurosis (eg, plantar 'fascia') <i>Accepted after November 15, 2010</i>
26989	Unlisted procedure, hands or fingers <i>Accepted before November 15, 2010</i>
J3590	Unclassified biologics
29130	Application of finger splint; static
99213	Office or other outpatient visit; evaluation and management of an established patient

Treatment of Dupuytren's Disease

The moderator for this discussion is **Prosper Benhaim, MD, FACS**, Associate Professor and Chief of Hand Surgery, UCLA Hand Center, UCLA Department of Orthopaedic Surgery, Los Angeles, CA. Joining him are hand surgeons **Charles Eaton, MD**, President, Dupuytren Foundation, Hand Surgeon, Jupiter, FL; **Vincent Rod Hentz, MD**, Emeritus Professor of Surgery, Stanford University, Stanford, CA. Chief, Hand Surgery Section, VA Palo Alto Health Care System, Palo Alto, CA; **Neil F. Jones, MD**, Professor and Chief of Hand Surgery, Department of Orthopedic Surgery and Division of Plastic and Reconstructive Surgery, UCI Medical Center, University of California Irvine, CA; and hand therapist **Saba Kamal, OTR, CHT**, Director Hands-On-Care, President American Society of Hand Therapists—California Chapter, Partner in Advanced Rehab Seminars, San Jose, CA

Dr. Benhaim: I think this is a very exciting time for Dupuytren's disease and its treatment. There has been a lot of national attention focused on this recently, with many new surgical nuances and differences in technique, especially with the gaining acceptance of needle aponeurotomy, the issue of collagenase and how they both are impacting our treatment options. There is still controversy as to what is the best type of open surgery—is it a classic dermatafasciectomy, palmar fasciectomy, or limited incision types of procedures? And, as you all know, patients have become much more savvy with the Internet and are much more informed than ever before. They come in with certain biases and we have to try to navigate our way through those biases.

I want to start off with Dr. Eaton, who put on a fantastic Dupuytren's symposium in May of this year. A lot of that symposium was based on some exciting research and some new developments in the basic science aspects of Dupuytren's disease. Charlie perhaps could give us an update.

Dr. Eaton: Sure. It's a very exciting time and there's quite a bit of basic science research that's going on globally. One of the fun things that came out of the symposium was getting people together who are working on similar topics but didn't know that the others were.

Basic science is screaming for more work in three areas: the first is

genetics. We have new genetic tools and very interesting research all around the world, but we're hindered by the lack of an animal model, and lack of a good starting point. We haven't yet clearly identified the problem chromosome, much less a specific gene. Could Dupuytren's be a retroviral infection or a spontaneous mutation? Dupuytren's is disproportionately common in European Americans compared to African Americans, so much so that it begs the question: is it a European gene, or is it the opposite, or maybe there's a gene from Africa which confers a special resistance to the causative factor of Dupuytren's? There's so much we don't know.

The second area is cell biology. TGF beta one is clearly a key player. Robson and others have shown in vitro that tamoxifen blocks the effect of TGF beta on Dupuytren myofibroblasts, and Degreef has shown that perioperative oral tamoxifen improves the results of fasciectomy. Should we be injecting palms with a depot version of Tamoxifen? TGF beta works by blocking nitric oxide induced myofibroblast dedifferentiation. Should we be studying the effect of putting nitropaste on the palms? The metabolic precursor to nitric oxide is arginine. Should we do trials of arginine supplementation? And Botox is not just the botulinum toxin, it also contains C3 transferase exonzyme, which blocks several steps in the pathway of fibrosis.

Botox is being reported as a treatment for keloid scars and botox has been shown to reduce contracture, adhesions and fibrosis after experimental surgical wounds. We should be looking at this.

The third area is demographics. We don't even know whether Dupuytren's is one condition or several, like diabetes. Maybe it's not unpredictable as much as it is heterogeneous. Abe in Japan, Bayat in the UK and Degreef in Belgium have extended the concept of diathesis to include risk factors of bilaterality, radial hand involvement, male gender, more than two fingers involved, age of onset under 50—all these are independently associated with higher risk of early recurrence. Studies which don't take these factors into account are comparing apples and oranges—in the dark. We need to use these in all future studies. Also, the fastest way to get meaningful results of treatment is to study patients with aggressive Dupuytren's, because they have a high likelihood of early recurrence which reduces the sample variation, compresses the time needed for

continued on next page



THIS IS A VERY EXCITING TIME FOR DUPUYTREN'S DISEASE AND ITS TREATMENT. THERE HAS BEEN A LOT OF NATIONAL ATTENTION FOCUSED ON THIS RECENTLY.

PROSPER BENHAIM, MD, FACS

Hand
Surgery
Quarterly

.....

Winter
2011

6

HAND TABLE

continued from page 6

results and magnifies the effects of treatment. We need to all get on the same page. We need to set up a global Dupuytren's registry.

Dr. Benhaim: I think those are exciting new insights into our understanding of Dupuytren's disease and they do spark some very important and interesting questions, especially with regard to the genetic and demographic features. I think we have all seen that, in fact, Dupuytren's is a very heterogeneous disease in its presentations.

Okay, Dr. Jones, at this point, what are your thoughts on conventional open fasciectomy? I know that you have done some work with limited palmar fasciectomy—types of incisions to try to reduce the amount of inflammation and post-operative recovery time, with some excellent results in your population of patients. Can you put into context for us what the role of conventional open fasciectomy is, and perhaps a little bit of a discussion on the advantages and disadvantages; and any pearls that you may impart to the audience with regard to minimizing the risk of complications associated with open fasciectomy?

Dr. Jones: Certainly. There are probably 3 basic types of fasciectomy—total, segmental and limited. Total or radical palmar fasciectomy—removing all the palmar fascia—has probably become obsolete. Most surgeons perform a segmental fasciectomy, only addressing one or two fingers. There are 3 types of incision: either you can do a longitudinal incision and convert it at the end with Z-plasties, or you can do Bruner incisions, or you can do the McCash technique, a transverse incision in the palm and occasionally transverse incisions in the fingers. Usually these are left open and allowed to granulate, but occasionally they can be skin grafted, usually with a full thickness skin graft. If I'm going to use the McCash incision, then I graft the defect, because they will contract if

you leave it open. I personally don't use the longitudinal incision—you end up with tiny Z-plasties and the tips of those flaps usually don't survive, and result in dehiscence or infection. So I use large Bruner incisions both in the palm and in the fingers. At the end of the contracture release, I gain increased length in the skin by using V-to-Y plasties.

I've been experimenting with fasciectomy through limited incisions for the past 7 years. It has been done in Europe and in England using small semi-circular flaps over the cord, and then excising small segmental portions of the cord through these small incisions. I use 2 or 3 small 1 centimeter long transverse incisions: usually one in the palm, one at the MP joint level and one at the PIP joint level. It's a very technically demanding operation, but I think it's safer than needle aponeurotomy because you can identify and protect the digital nerves. Rather than just dividing the cord with the needle and leaving behind remnants of the cord to reform, you can excise a complete 1 cm segmental defect in the cord. Sometimes you can work from transverse incision to transverse incision and completely excise the entire cord, but you need a very good assistant.

The problem with Dupuytren's surgery is that you can get most of these fingers fully straight, but in doing so, they may lose full flexion. So the basic concept of the limited incision technique is that you want to regain finger flexion as fast as possible, hopefully within 3 days and certainly by 10 days to 2 weeks so that patients require minimal post-operative hand therapy. Dr. Eon Shin has submitted our series of patients who underwent Dupuytren's release through limited incisions with a 2-year follow up and these results are very gratifying.

Dr. Benhaim: Do any of the members on this panel modify the conventional Bruner incisions, or perhaps prefer to use a longitudinal incision with multiple Z-plasties in the severely contracted finger, where there may not be enough skin—at

least theoretically—to go from severely flexed to fully extended?

Dr. Hentz: I will frequently use a straight-line incision and do Z-plasties, although usually larger Z-plasties. I'm quick to use full-thickness grafts in the severely contracted individuals because they're so short of skin that the manipulation that you have to do at suturing the skin creates the background for that stiffness. So I'm quick to use full-thickness grafts even in an unoperated, first-time procedure if they are severely contracted.

Dr. Benhaim: If you do use a skin graft, how does that modify your rehabilitation? Do you keep the hand immobilized for 10 days or longer? How do patients do when they've had a skin graft and had a 10 or 14 day delay in mobilization to allow the skin graft to take?

Dr. Hentz: I immobilize. I use a bolster—like most of us do—and remove the bolster about day 4, and start them moving. And by day 4 the grafts are vascularized enough to allow motion. I start them moving real early.

Dr. Eaton: I don't start them quite as soon as that—a week is more my preference. I know some surgeons will completely immobilize for 3 weeks after dermofasciectomy and skin graft, and I've seen some good results of other patients who have had that type of protocol. But I still think that early mobilization is key because lack of flexion is a significant long term problem.

Dr. Jones: I definitely use full thickness skin grafts, although I am not



THE BASIC CONCEPT OF THE LIMITED INCISION TECHNIQUE IS THAT YOU WANT TO REGAIN FINGER FLEXION AS FAST AS POSSIBLE SO THAT PATIENTS REQUIRE MINIMAL POST-OPERATIVE HAND THERAPY.

NEIL F. JONES, MD

Hand
Surgery
Quarterly

.....
Winter
2011

7

continued on next page

HAND TABLE

continued from page 7

as aggressive in moving them as Dr. Hentz. I splint them in full extension for a week and then let them start moving. However if I'm doing a primary Dupuytren's release without any skin grafting, I move them very quickly, usually by the second or the third day.

Dr. Benhaim: Saba, can you address, in a more global fashion, your concept of when patients who have had open fasciectomy, with or without a skin graft, should start therapy? Do you think there is a big difference in the outcome if you start therapy on day 1 versus 3, or even day 7 or 10, if you have had to protect the skin graft for perhaps a week or so?

Ms. Kamal: The way we normally treat Dupuytren's patients is for early range of motion. If it's just open fasciectomy without a skin graft, the patient is splinted on the second day in a hand-based splint. If the patient had multiple fingers worked on resulting in a swollen hand, then we let them rest for a couple of days, to allow for the inflammation to subside, and then get them moving. If the patient had a skin graft, in order for the skin graft to take, the patient is usually referred a little late, at 3 days rather than the day or two after surgery. So we keep them in the splint for that week, and then start moving them. Some patients I've known at other places have had a forearm included in the splint. We usually don't do that because it causes a lot of wrist stiffness later down the road. But light range of motion early on and then slowly progressing them through the different stages of therapy allows for that early range and prevents that flexion stiffness that a lot of people complain about as we go on.

Dr. Benhaim: Two of the panelists have already suggested that one of the main problems with these types of surgical procedures is not so much that the patients can't necessarily get all the way straight, but

they have trouble making a tight fist afterward. In my practice, one of the most frustrating aspects of Dupuytren's surgery is the frustration that the patient feels with the inability to make a tight fist. Have you noticed any specific type of patient or condition that would predispose a patient to that type of outcome? Do you have any tips for us as to how to prevent that, from a therapy perspective?

Ms. Kamal: Sure. Usually patients who have had a volar plate release tend to develop adhesions at the Zone II level. We try to address this early: first, we address this by gentle early passive and then active ROM, which includes tendon gliding and especially differential gliding. Edema management is done with 3/4 finger gloves to allow them the tactile feedback to encourage use of the hand yet provide compression for the swelling. Once the sutures are healed, we therapists remove the sutures for the surgeon so that we can start the scar massage early on rather than waiting for the sutures to be removed later or too early and construct a scar mold. One of the things that really tends to help is flexion wrapping, that is wrapping the finger in flexion to get full passive range of motion. If they don't have that, obviously they're not going to get the full glide, the differential gliding and thus the active motion that seems to frustrate these patients. If we do notice an adhesion developing around Stage 2 or 3 of Dupuytren's healing stages, we add neuro muscular electrical stimulation (NMES) to get those tendons to pull through the scar adhesions (something we use in flexor tendon management) and that seems to help with maximizing the active range of motion limitation that some of these patients may present with.

Dr. Benhaim: Dr. Eaton, you have been injecting patients with steroid after a needle aponeurotomy. Does anyone here also inject steroid after conventional surgery?


Dr. Hentz: I've not done that.

Dr. Jones: I haven't used a steroid injection after segmental fasciectomy but I have used it after a needle aponeurotomy. However, I'm not sure it does any good.

Dr. Eaton: The data on it is still lacking. I routinely infiltrate the needle aponeurotomy portals with a few milligrams of Kenalog at each site. The basis of this is that we know that local steroid injection modulates the

Dupuytren's biology, and that it's followed fairly quickly by loss of myofibroblasts in the area and to a certain extent turning off the main biology. Long term effects I'm not sure of, and the other thing that makes it hard to assess—and a study needs to be done to look at this—is that after a fasciotomy, over a few weeks, adjacent nodules will soften up and become less prominent. That's probably just the effect of taking the tension off of the tissues that are attached to the nodule, and traction and tension on the Dupuytren's tissue. Laboratory work very clearly shows that tissue tension provokes the whole biology, so it may be that the softening that you get after a steroid injection is from the steroid but it also may be a mechanical effect.

Another other thing to throw in the mix is Lynn Ketchum's experience with injecting steroids into nodules. A refinement of that is if you inject steroid into a nodule without an associated cord, a nodule in the palm, it's fairly predictable that the nodule will go away, at least temporarily, and that can be very impressive. However, if



...COLLAGENASE IS A LITTLE TOO GOOD. IT WORKS TOO WELL IN THESE NICE CASES THAT YOU LOVE TO SEE WALK INTO YOUR OFFICE BECAUSE YOU KNOW YOU CAN DO YOUR SURGERY AND THEY'RE GOING TO BE HAPPY, AND YOU'LL BE HAPPY.

VINCENT ROD HENTZ, MD

Hand
Surgery
Quarterly

.....

Winter
2011

8

continued on next page

HAND TABLE

continued from page 8

you inject a nodule in the palm that is associated with a contracture and a palpable cord, it doesn't respond as predictably.

The third thing is that if you inject nodules in the fingers associated with some contracture, it may actually provoke or accelerate the ongoing contracture. So all of that needs to be made more clear with additional studies. In the meantime I inject after doing a release just to help smooth the post-operative recovery.

Dr. Jones: There's a detrimental side effect of steroids if you're doing a segmental fasciectomy. You may get delayed skin healing and potential dehiscence of the incision if you move them too early. I have not used steroids in conventional Dupuytren's surgery for this reason.

Dr. Benhaim: The traditional treatment after doing a palmar fasciectomy, or even a needle aponeurotomy, is to place the hand into an extension splint with the fingers in full extension. Others have suggested that this perhaps places the tissues under some tension, which can increase the inflammatory response after surgery. What is your current splinting protocol after an open fasciectomy for a patient who has had a couple of fingers released? Do you place the fingers in full extension, or are you putting just a partial extension split to try to take the tension off the incisions/skin flaps and try to minimize the inflammatory response? Do you worry at all that not placing the fingers in full extension may lead to losing some ground rather quickly, even just a few days after surgery?

Dr. Hentz: Probably everyone has a different approach. I will do the fasciectomy and make sure that I can get the fingers as extended as I hoped—that may not always be fully extended, but at least I try to achieve my and the patient's goals. But once I've done my closure, whether it's with Z-plasties or with

zigzag incisions—and as Dr. Jones has said, a V to Y advancement to gain a little soft tissue length. splint them in a comfortable position. My feeling is that if you are stressing your skin flaps then you are creating some ischemia and that's going to initiate an ischemic cascade and potentially affect the healing. We get into problems if we make these patients uncomfortable. So I splint them in a comfortable position and then they start moving relatively early, say 3 or 4 days. We know from our biological studies that it takes a few days for scar to form, so I'm not worried about a lot of scar forming in 2 or 3 days. I don't feel that you need to splint these people in extremes of positions.

Dr. Eaton: I would agree with that: I think people have less inflammation afterward. I only splint after a dermofasciectomy and skin graft, and then only in the resting posture of that hand. The whole issue of splinting has lacked evidence until fairly recently, and what is starting to come out goes against a lot of tradition. Roslyn Evans compared traditional passive extension splinting with only active extension and found that avoiding passive extension gave fewer post-op wound healing problems, lower instance of flare and a better final range of motion. The Norwich Dupuytren's group in England has taken this one step further and I don't think they've published this yet, but they looked at routine night-time splinting versus splinting only if patients started losing extension post-op. They looked at patients who were compliant versus non-compliant wearing their splints, and they found at a year post-op that both patient satisfaction and total active extension were better in those who did not wear night-time splints. That turns some things on their head, but there's another area that we need to look at. It may be that common sense of splinting in extension may not be that sensible.

Dr. Jones: I'll play the devil's advocate. Obviously, there are some patients that you can't achieve full


extension, especially at the PIP joint but you should be able to get the majority of patients fully extended with meticulous surgery. Even if they have a 90 degree contracture at the MP joint, you should be able to achieve full extension, but full extension at the PIP joint may be limited by secondary changes in the volar plate, collateral ligaments and the flexor tendon sheath. If I can't get the finger fully extended at the PIP joint, then

there's obviously something secondarily affecting those other structures and I may not be able to get the finger fully straight. But I splint all fingers as straight as I can achieve surgically. If you don't splint them as straight as you can, I think you lose ground right from the start. Similarly, I disagree with the Norwich group, because many of my patients tell me that they start to see their finger flex down more if they stop using a night splint in the first few months. If they start night splinting again, they can regain that lost extension quite quickly.

The only time I do not splint a finger completely straight is if there's any compromised circulation to the finger. Then I usually flex the finger just a little bit for the first day or so and consequently relax any tension on the incisions and the digital arteries.

Dr. Benhaim: Saba, do you have any input on this?

Ms. Kamal: We normally splint our patients in complete extension. However, we provide enough padding for the patients to work through that extension rather than



THERE'S QUITE A BIT OF BASIC SCIENCE RESEARCH THAT'S GOING ON GLOBALLY [..ON DUPUYTREN'S DISEASE]. WE HAVE TO PUSH TO HAVE MORE WORK DONE TO FIND BIOLOGICAL TREATMENTS.

CHARLES EATON, MD

Hand
Surgery
Quarterly

.....

Winter
2011

9

continued on next page

HAND TABLE

continued from page 9

forcing them in extension so that they are able to do it at their comfort level. This prevents a CRPS response and the sutures from pulling out. However, we're seeing that if the patients don't wear the splint they actually do start to lose ground. And the patients are also educated that if during the day they do see that the finger starts to droop, they're just supposed to put it on for an hour or so—that way they regain the function but not lose extension and yet continue to gain flexion. The intricacies are in the padding: how the padding and the splinting is done to gain the extension at the right joint, providing a subtle 3-point pressure with the foam padding with the amount of padding that's placed in, and allowing the patients to do it at their own pace. Also, we do instruct the patients to continue to wear the night splint for 6 months regardless of family history/recurrence, and the patients are more than happy to comply.

It's the principle of stretched relaxation, that as the tissues relax they automatically extend out rather than forcing them through aggressive stretching, because that will just increase swelling and further the contracture.

Dr. Benhaim: I think one of the most difficult patients that we see is the young patient who has very extensive disease at early onset, with associated ectopic disease sites, such as Ledderhose Disease, Peyronie's Disease, or knuckle pad formation on the dorsal aspects of the PIP joints. What is the panel's thought on how you treat these patients? Is anyone doing an initial minimal approach with needle aponeurotomy? Do you go straight to palmar fasciectomy because you know that the recurrence rate is going to be extremely high? Do you go extreme and do something like a dermatofasciectomy with skin graft? What is the general thought on how to approach these patients?

Dr. Eaton: I have an unusual demographic of patients—most of the folks who I see with Dupuytren's don't want open surgery. And that's even if these folks have a lot of risk factors for early recurrence. And after explaining options to them and even knowing that they may get fairly short improvement, many of these folks will request needle release. Interestingly, not all of them have dramatic early recurrences, which shows that even with known risk factors you can't always predict outcome. But I think for someone who looks like they have very biologically aggressive disease that places them at high risk for early recurrence, you could do a minimal approach with a needle release, or collagenase. If their biology doesn't turn out to be as bad as you think it is, great. However, if they show that they have very aggressive biology, they are probably going to flunk fasciectomy as well. And you could make the case to make their first open operation dermatofasciectomy and skin graft. And I think that has an advantage of not having dermatofasciectomy and skin graft being the 2nd or 3rd operation. That's where people run into trouble. They're operating in very scarred terrain on the final operation.

Dr. Jones: Patients are much more educated now and they may even know what Dupuytren's diathesis is and they obviously know about needle aponeurotomy. So I have no problem doing a needle aponeurotomy as the initial operation in somebody with Dupuytren's diathesis, but I tell them what they may probably develop in the future. My own opinion about the diathesis is that you need to operate on these patients sooner rather than later. That means I will operate on any finger with a 30 degree contracture at the MP joint or the PIP joint. I will do a segmental fasciectomy in two or even three or four digits—but I don't usually skin graft them if I operate on them early. However, if they then recur again, usually the second time around, then I will use a full-thickness skin graft based on Hueston's "fire-break" concept.

Dr. Hentz: I've found it hard to convince somebody that has these risk factors associated with the diathesis, a young patient with disease in several fingers who's never had any treatment, to accept having a good bit of his palmar skin removed and full thickness skin grafts. Even though it may be the best in the long run for them, it's hard getting them to agree to it. So my approach, like Dr. Jones', has been to do a more standard operation.

However, I encourage them to have it done earlier as opposed to waiting until it bothers them a lot because I think that the operation certainly is easier.

If they do recur, which many of them do, I'll do a limited fasciectomy, excise all damaged and scarred skin of the proximal phalanx and place a big skin graft as opposed to another big fasciectomy. I've not seen so many folks who I thought were great candidates for needle aponeurotomy because they frequently have these big, thick nodules—many of them have PIP contractures, and their disease is in the form of a big nodule that's occupying a lot of the proximal phalanx. I have a hard time conceptualizing how I'm going to affect that with a needle or with a collagenase. It's like trying to melt a glacier by pouring a teacup of hot water—it's just not going to happen. So for those folks my initial procedure is a fasciectomy. Maybe a little bit more extensive, but still a fasciectomy.

Dr. Benhaim: Dr. Eaton, do you have a response to that?

Dr. Eaton: The difficulty with fasciectomy on people with aggressive Dupuytren's is a lot of them don't come back even when they have a



THERAPISTS SHOULD ASSIST WITH REMOVAL OF SUTURES TO START PROMPT SCAR MANAGEMENT AND PREVENT ADHESIONS OF THE FLEXOR TENDON.

SABA KAMAL, OTR, CHT

Hand
Surgery
Quarterly

.....
Winter
2011

10

continued on next page

HAND TABLE

continued from page 10

recurrence. So it's hard to sort out the long-term results. I think the long-term results of dermofasciectomy and skin graft are more predictable in these folks than simple fasciectomy, but I would agree that if they've had a fasciectomy that first time, the second operation shouldn't be a repeat of a radical kind of fasciectomy but rather a SWAT mission to replace whole zones of skin and not trying to filet out all the fascia. The business of a firebreak skin graft is also interesting. Dias has shown that small firebreak skin grafts are no more effective than fasciectomy alone. So I think the key, as has been said, is to

have a big skin graft if you're going to use one.

Dr. Benhaim: Great. The patient with the fairly significant contracture of a PIP joint may have had that contracture for many years, and may have developed a secondary PIP joint volar capsule contracture that is independent of the Dupuytren's disease itself. I think we have all been in the situation where we have done a very thorough and extensive release of the Dupuytren's disease, either by needle aponeurotomy or by conventional open technique, but find that there is still a 20 or 30 degree PIP joint contracture that is really not due to either Dupuytren's cord or retrovascular disease, or even disease immediately underneath the

skin. We have released everything that we can possibly release, yet there is still this residual PIP contracture. What is your approach to that patient? Do you ignore it? Do you do a PIP joint closed capsulotomy? Do you actually open the flexor tendon sheath and do a formal open PIP joint capsulotomy? What is your approach?

Dr. Hentz: There are lots of different ways to do this. First off, for those people I spend a little more time counseling them basically to determine what their risk factors are and what their expectation is. So I go into the operation with some sense of how aggressive to be in that circumstance where they have a PIP contracture. Usually these are going

continued on next page

Hand Therapy Techniques for Stages of Dupuytren's

Saba Kamal, OTR, CHT

Stage I: Immediate post op Day One after surgery

Splinting: A hand based splint should be fabricated with open foam padding to increase gentle PIP extension, i.e. a dorsal padding is applied on P1 on the splint and volar padding is applied on the straps.

Splinting is done for night time only if a single digit is involved that does not have much swelling, however, if the patient presents with a multi-digit involvement and a balloon hand, the splint is left on for 3 days, day and night to allow for the reduction in swelling. Pt. removes the splint only for exercise. If skin graft is done the splinting is left on for 1 week to protect the graft then ROM is started. No aggressive extension should be done to minimize the risk excessive swelling, incision opening up or CRPS. If the nerve is involved, the joint involved is kept on slack. However, if volar plate release is done then PIP joint issues need to be taken into account.

Edema: If pitting edema is present, heat with elevation needs to be done, followed with retrograde massage and gentle passive ROM.

In this stage wound care, heating the hand in gentle flexion, gentle ROM, tendon glides, management of swelling should be done.

Stage II: 10-14 days after suture removal

In addition to the above, therapists should offer to remove the sutures as the incision heals, this accelerates the scar management process. Once sutures are removed adding paraffin/heat with stretch in flexion, gentle exercises like peg rolls (graded large to small), extension exercises (putty roll), last exercise must be an extension exercise. Along with this providing scar mold, scar massage, edema glove etc. is helpful. Patient is instructed in wearing the splint during the day, if they notice any drooping of the finger, for at least an hour to restore the extension.

Stage III: Decrease in swelling, presence of full passive ROM

Add more aggressive strengthening with putty gripping and

extension exercises, Velcro boards etc, use LMB for PIP joint management if it has a soft end feel and NMES if active ROM deficit is present in flexion. End ROM is achieved with static progressive splinting.

Principles of stress relaxation with splinting should be taken into account in the initial stages and principles of creep in the later stages of splinting.

Stage IV: Full active and passive ROM

Heavy gripping exercises dynamic gripping with pro hand gripper (graded gripper), (grip-move-place-release) with different sized pegs, end range extension with static progressive splinting during the day and continue with night extension splinting for 6 months. Emphasis should be placed on educating the patient at every visit, on the importance to wear the splint at night for 6 months after the surgery to prevent recurrences.

Tip: Conservative management: Adding scar mold in the night splint provides a gentle stretch to the tissues when managing very early stages of Dupuytren's disease.

HAND TABLE

continued from page 11

to be the folks that have 45 to 60 to 70 degrees, it's been there for a while and you've searched everywhere for those cords. Since I started rereading McFarlane's articles, I've searched in areas that I didn't search before and have found cords that I've removed and had better results. But if you have made a good search and now you're faced with what to do, how aggressive to be with the rest of the peri-articular structures, I usually will start out with gentle manipulation which is kind of a closed capsulotomy, because sometimes that's all they need. You'll feel a little stretch and a little semi-tearing, but the joint comes much straighter and you don't have to go do a lot of incising. If that doesn't work and the patient and I have agreed on the level of aggression, then I will systematically start releasing things until I've achieved what I think the patient wants me to achieve. Now if they're in a 60 to 70 degree range and it's

been there a long time, I have counseled them ahead of time—particularly if it's the 4th and particularly the little finger—more than likely their extensor mechanism is now so stretched that they're not going to keep the correction that I might get at the operating table. I may get them nearly straight, but if it's a 5th finger and it's been at 60 or 70 degrees for a good while, they're never going to keep that extension because their extensor mechanism is now overstretched. I modify my discussions with the patients based upon those factors.

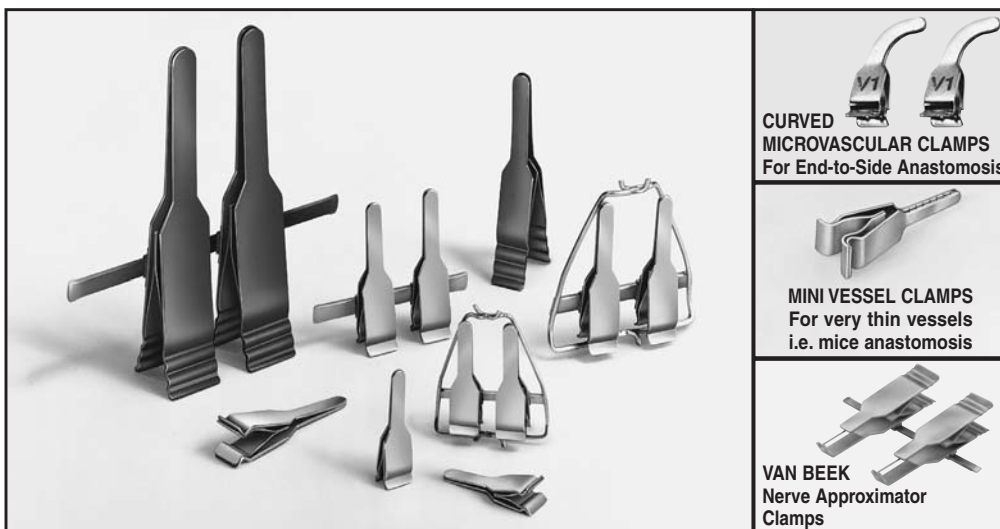
Dr. Jones: I agree almost completely with Dr. Hentz. It is very important to look very carefully for retrovascular cords and in the little finger for cords arising from the hypothenar muscles. If the patient still has a residual contracture at the PIP joint after you have released the cords, then I incise the flexor tendon sheath between the distal end of the A2 pulley and the proximal end of the A4 pulley, because many times there's a contracture in the flexor tendon sheath itself rather than in the collateral ligaments or

the volar plate. Just like Dr. Hentz, I perform a gentle manipulation of the PIP joint into extension and if necessary a closed capsulotomy, but I no longer do an open capsulotomy releasing the volar plate and collateral ligaments with a scalpel. An open capsulotomy tends to result in a dramatic loss of flexion of the finger. It's very much like camptodactyly in which you can get the finger straight, but they then lose flexion. I counsel these patients before surgery, so that if their finger can be improved from let's say a 60 degree PIP joint contracture to 20 or 30 degrees and they maintain good flexion, that's a much better functional finger than if we had achieved full extension but now they lack touching the distal palmar crease by 2 centimeters.

The final very important point that Dr. Hentz made, which was initially described by Paul Smith in England, is that if the patient has a long standing PIP joint flexion contracture, the central slip may have become attenuated, just like an ulnar nerve palsy. Even if you get

continued on next page

ASSI[®] MICROVASCULAR CLAMPS CHOSEN BY THE BEST BECAUSE THEY ARE THE BEST!



CURVED MICROVASCULAR CLAMPS
For End-to-Side Anastomosis

MINI VESSEL CLAMPS
For very thin vessels
i.e. mice anastomosis

VAN BEEK
Nerve Approximator
Clamps

assi[®]
ACCURATE SURGICAL & SCIENTIFIC INSTRUMENTS[®]
For diamond perfect performance[™]

accurate surgical & scientific instruments corporation
516.333.2570 fax: 516.997.4948 west coast: 800.255.9378
800.645.3569 www accuratesurgical.com

Hand
Surgery
Quarterly

.....
Winter
2011

12

HAND TABLE

continued from page 12

the finger straight, the central slip will not be able to maintain that. Paul Smith has shortened the central slip, but I've not done that myself. I would be very cautious of doing it because even if it achieved a fully straight extended finger, the patient may then not be able to fully flex their finger.

Dr. Eaton: I agree with all of that. I think that a closed manipulation can be very helpful. I think that the flexor sheath is often part of the problem of a secondary force resulting in contracture. I think the literature is clear on the long-term ineffectiveness of open PIP release at the time of fasciectomy. Separate studies by Weinzweig, by Richie and by Byerman all showed intra-operative gains from PIP capsulotomy are lost at one year post-op. Buck-Gramko showed that PIP arthrolysis and pinning led to flexion loss but not extension gain. Long term, you can make things worse, but not better with open capsulotomy.

Dr. Benhaim: I'd like to move onto needle aponeurotomy. As you all know, this has become an increasingly popular technique as a less invasive alternative to conventional open palmar fasciectomy. It has not, however, been widely adopted as a mainstream technique by perhaps the majority of hand surgeons still in 2010. I guess the area of interest for me is why do you think there has been such resistance to universal adoption of needle aponeurotomy? Are there some basic simple ideas that you might have as to why surgeons have been a little bit resistant to adopting this as a mainstream technique for a good proportion of our hand surgeons?

Dr. Hentz: Charlie should answer this question, but I will make this one comment. I think that there may be many closet needle aponeurotomers.

Dr. Eaton: I think that's true. I think there are a couple reasons. The simplest one is there's inertia in new techniques. Unless surgeons are really compelled by a great financial incentive or by a legal incentive, change is often slower than we would expect. I think another issue is that it sounds like it's stupid and dangerous, and the idea of doing a blind procedure in the palm is something which most hand surgeons' initial reaction—including mine when I first heard of this—was "...well, that's just a bad idea, that's just asking for trouble...", and then they don't think about it again. I think that's the reason why the interest in needle release is patient driven, because the patients know all these horror stories of fasciectomy and people they know that have had problems and they're looking for their treatment options really almost more than the surgeons. But I think the main issue is just inertia, plus a lot of hand surgeons have postponed looking into needle release because it looked as though the next step was going to be collagenase.

Dr. Benhaim: So Charlie, perhaps you could give us a brief primer for the surgeon who may be contemplating needle aponeurotomy as a technique in his or her armamentarium. What are your general indications and contraindications to needle aponeurotomy? Are there any simple basic technical pearls that you think are important before someone starts performing this technique?

Dr. Eaton: The first is to read about or observe the basic technique from somebody who has experience. The big concerns that people have are avoiding nerve and tendon injury. This really requires the proper intradermal anesthetic technique. The mantra is if the fingertip is not numb, and if there aren't any paresthesias, and if active finger range of motion doesn't catch the tip of the needle, then you're doing no harm. The technique description and videos of this technique are available online, and coming up in print publication. But the minimum requirement is contracture from a

palpable cord, in an area where there's some skin reserve, and cooperative patient. The ideal starter patients would be folks who don't have big beefy hands, but have relatively soft skin, isolated MCP contracture, with a clear MCP cord. And there is a learning curve, as with any technical skill it takes a little while to get the feel of the needle and the feel of how the whole thing proceeds. But in general, starting out on relatively safe cases with isolated MP contracture not terribly severe is a fairly predictable way to get an improvement, the patients are happy, and you can advance from there.

Dr. Benhaim: Dr. Jones, you have done both a lot of open surgery and some needle aponeurotomy. How do you make the decision to use an open versus needle technique in a particular patient?

Dr. Jones: Dr. Hentz and Dr. Eaton have talked about this being patient driven, and I think these patients come to you already having decided that they want a needle aponeurotomy and I can understand that, but there are some patients that I don't personally think are suitable candidates for it. So I will tell them that in my experience their particular anatomy does not lend itself to a needle aponeurotomy and I also tell them that this is not a panacea. If you look at the few long-term follow-up studies of needle aponeurotomy and if you follow your own patients, and maybe Dr Eaton will counter this, there is a significantly high recurrence rate around 65% at 2 years. It obviously depends on how you define recurrence. Once I've explained this, then I let them make their decision. To me the ideal candidate for needle aponeurotomy is someone with relatively thin skin; somebody who has what I call a very central cord – I don't want a cord that is situated in an area where I know the digital nerves are likely to be. Certainly an isolated MP joint contracture is going to be much easier than combined MP and PIP joint contrac-

continued on next page

continued from page 13

tures. Finally, I don't want a patient with a very large nodule sitting over the palmar aspect of their PIP or DIP joints. So those are some of my indications and contraindications for doing needle aponeurotomy, and I just let the patient make their decision. If they don't take my advice that they're not a candidate for a needle aponeurotomy, maybe they go off and have it done by somebody else anyway.

I will also just make two other points. One is when you asked about why surgeons are loathe to take it up, I think it's just like a lot of other minimally invasive surgery like endoscopic carpal tunnel release. If you can't see the anatomy, then I think many surgeons are reticent or fear damaging a structure and being exposed to the legal system. And I would counter that by suggesting the next time you do a Dupuytren's that you're going to do open, just try needling the cord in the palm, and then incorporate the needle portal in your incision and see just how much of the cord you've released and see how close you were to the digital nerve and the flexor tendon sheath.

My final point is that I use needles a lot in the very severely contracted finger that I'm going to do an open fasciectomy on. If you use a needle right at the start, you may be able to extend the finger a little bit more and be able to get the finger into the lead hand. So that's another very useful trick for using needle aponeurotomy.

Dr. Benhaim: One of the main criticisms of needle aponeurotomy is the higher recurrence rate reported in the literature. Are there any techniques that you use, Dr. Eaton, to minimize the risk of recurrence after needle aponeurotomy?

Dr. Eaton: In theory, more thorough releases to relieve cord tension should result in slower recurrences, but this really has to be studied. The one study that is the most recently reported is from Paul

Werker's group. He reported an 85% recurrence rate at 5 years; and the problem that I have in comparing that is because of the demographic of my patients it makes it difficult for me to have follow ups since so many come from a distance. I don't have the numbers to either confirm or refute that. I do know that the technique that was used was more similar to the technique that was developed in Paris, which is to use one or two portals or levels of release, give a strong pull, and get as much improvement from that as can be. I suspect and I'm hoping that the numbers will ultimately show that by releasing at more levels and resulting in a more diffuse release of tension along all of the diseased tissue, that the affect will last longer. But ultimately it comes down to the fact that Dupuytren's is not a surgical disease, it's a medical condition that does not yet have a medicine; and trying to come up with the best operation for Dupuytren's is kind of like trying to figure out which is the best hammer to sweep water out of your driveway in the rain. It's just the wrong tool. It works to a degree, but we have to push to have more work done to find biological treatments.

Dr. Benhaim: So that brings us to the next question, which is the closest that we have to a biological treatment, which is the recent approval by the FDA of collagenase for treatment of Dupuytren's disease. Clearly, this does not address the underlying cause, but it does allow us to attack the collagen in a non-surgical fashion. Dr. Hentz, you have been involved in some of the initial studies and I know that you have a lot of experience with collagenase. What are your current thoughts on the role of collagenase in your treatment of these patients? Is there a particular set of indications or contraindications that you use in your current practice in patients who have not had any prior treatment?

Dr. Hentz: My comments when I'm asked that by my colleagues has recently been that collagenase is a

little too good. It works too well in these nice cases that have in my experience been the cases that you love to see walk into your office because you know you can do your surgery and they're going to be happy, and you'll be happy. The current indications for collagenase in my practice is almost anybody that has a palpable cord—as opposed to that big nodule that I talked about that occupied most of the proximal phalanx. And I'm trying collagenase in essentially all comers who first receive informed consent about the various treatments. If they still want to try collagenase I am using it in almost any location where I definitely have a target that's not adjacent to the flexor tendon. And so I think the indications are still being developed and our success rate in the patients that we've done since the drug was released by the FDA—has been significantly better than our results during the clinical trials. I think that's due to the fact that we can anesthetize these individuals when it comes time to do the 24 hour or 48 hour post injection manipulation. That lets us be a little bit more aggressive, and my results are better in these 18 or 20 folks that I've injected so far outside the clinical trials, than in the 30 or 38 or 40 folks that we had in the clinical trial.

Dr. Benhaim: Dr. Jones, have you had any experience with collagenase? If not, what are your concerns about its use?

Dr. Jones: I've just started to play with collagenase, but maybe I'm a little more skeptical and have concerns regarding the recurrence rate and injury, similar concerns related to needle aponeurotomy. Collagenase does not distinguish between a Dupuytren's cord and the flexor tendon and 2 flexor tendons ruptured in the original collagenase trial and all those injections were performed by hand surgeons. If you look on the Auxilium website, there are far more "other physicians" as opposed to hand surgeons

continued on next page

HAND TABLE

continued from page 14

“accredited” to use collagenase. So I have great concerns that in the future, some patients may end up with a far worse problem with a flexor tendon rupture due to collagenase being injected into the flexor tendon sheath or into a tendon. If you have collagenase injections

being done by physicians (other than hand surgeons) who do not have a specialist’s knowledge of hand anatomy, then I think there’s going to be a greater propensity for the collagenase to end up in areas other than the cord itself.

The second issue is the rate of recurrence. Dr. Hentz recently published a very small series and reported that 60% of MP joint contractures recurred at 8 years, to

about half of what the original contracture had been, but the recurrence rate of PIP joint contractures was literally 100%.

I believe both collagenase and needle aponeurotomy are not a definitive cure for Dupuytren’s, but have a role in the initial treatment of Dupuytren’s. The risk of needle aponeurotomy is injury to the digital nerves; the risk of collagenase is

continued on next page

HAND THERAPY PROFILE

Charleen Stennett, OTR/L, CHT

Personal: Originally from Jamaica, and upon moving to the United States, Miami became my home. When not working at the office, I love to play tennis, run, spin, rollerblade, watch movies, shop and travel. I especially enjoy creating and sharing new and wonderful memories with family and friends.

Education: Attained an A.S. from Miami Dade Community College in 1991 and then graduated from Florida International University with a B.S. in Occupational Therapy in 1994. I received my certification in Hand Therapy in 2003.

Employment: Currently working for The Hand Institute in Miami, Florida with renowned hand surgeon Dr. Jorge Orbay. I have had the pleasure of working by his side for 15 years. I am privileged to serve as both full time hand therapist and director of rehabilitation services for the hand and upper extremity practice.

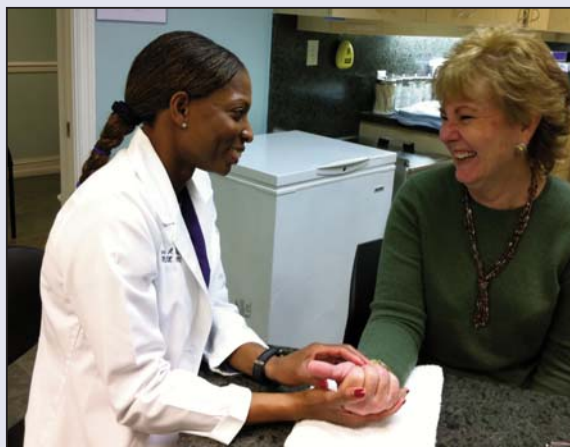AAHS Involvement: Associate member since 1999. I have had the pleasure of attending numerous conferences at exquisite locations. Exceptional educational and networking opportunities are afforded consistently.

Best Part of My Job:

There is a culture at my work place that is complementary. Having a physician readily available observing and challenging is a great support and show of trust. Watching him listen as patients share their gratitude of met goals. Working with a knowledgeable, efficient and congenial staff is heartening. Witnessing a wide spectrum of patient injuries, keeps me grounded and challenged to strive to continue to provide the most innovative care.

Major Accomplishments: There are three milestones that I cherish dearly. The first one being my over twenty years military service in the United States Army. The second is the privilege of conducting lectures in my field within the US and South America, and being able to offer the South American lectures in Spanish, a long held wish. The third is having become a Certified Hand Therapist in 2003. I continue to strive for the ultimate pinnacle of personal achievement.

Clinical Specialties: I truly enjoy the wide spectrum of patients that arrive at our facility. I especially like acute trauma injuries that force creativity and critical thinking out of the norm. I treasure splinting and wound care.



Greatest Professional Challenge:

Providing the highest level of quality patient care to my patients has always been my mantra. Of late, it has been a balancing act of the most extreme kind. This due to reimbursement and number of visit curtailments as imposed by insurance companies. The situation is further exacerbated by increased copayments for the already cash-strapped patients. For the institution, the impact has led to forced adjustments and in its wake has left meager financial resources for salaries, supplies and the like. On the part of our patients, we have experienced less time with them again caused by the affordability gap. It is not quite yet a crisis, but the emerging realities appear very undesirable.

Three Words That Describe Me:

Independent, empathetic, adventurous. **H**

HAND TABLE

continued from page 15

rupture of a flexor tendon, but I suspect the rate of recurrence after both techniques will be very similar.

Dr. Benhaim: I would love to get Dr. Hentz's thoughts on recurrence rates, but before I do that, I would like to hear Dr. Eaton's input on collagenase, given his very busy Dupuytren's practice.

Dr. Eaton: I am intrigued, but have not yet used it for two reasons. One is that I haven't yet seen a situation for which I thought that it offered a real advantage over doing a needle release. The other is that I see people from a distance, and to organize a several day visit and the follow up afterward, logistically is a little bit of a problem. I agree with Dr. Jones that I don't think that it's ultimately going to be a biologically superior intervention because you do get recurrences afterward. I am intrigued by the reports of doing fasciectomy following collagenase, and fasciectomy following needle release. You do get some scar tissue in the subcutaneous and deeper tissues after doing a needle release in my experience and others. The people that I've talked to have done fasciectomy following a recurrence after collagenase have described the tissues as actually being in fairly good shape, and concerns about gross architectural derangement from the effect of collagenase have not borne out. The tissue planes seemed to be pretty well preserved, and so that may actually be an advantage.

Dr. Benhaim: Dr. Hentz, your thoughts on recurrence rates after collagenase treatment?

Dr. Hentz: Well, we don't know. And that's both the long and the short answer. The paper that Dr. Jones alluded to was our follow up of the Phase II dose response trial that was done in 1999. We tried to get as many folks back at about 8 years after the treatment as we could, and of the few we did get back, we found that folks that had MP con-

tractures that had a good response from the dose response study—in other words they came essentially straight—maintained themselves pretty well. Some of them had new disease, but not to the point where you would even consider offering surgery for them. The PIP was another matter, and because many of those folks didn't respond very well during the dose response trial—they didn't come all the way out straight—they had residual contracture at the end of the dose response trial. When they came back they had fairly significant worsening of their PIP contractures.

For the most recent trial, there is an extension study going on to look at what happens over 5 years, and we're coming on the year 3 anniversary for that. The year 2 anniversary data was put out and it showed that of all of the people in the Phase III trial—there were 200+ subjects who got the collagenase—19% now have some evidence of disease. They didn't have a contracture necessarily, but you could feel that there was something there that wasn't there a year before. So at 2 years they were not recurring to the point where you would treat them, but 19% had something that you could feel. And I suspect that number will go up at the 3rd year and the 4th year and the 5th year. And I can't agree more that collagenase is not a cure. It's just a different tool. I think it has some safety advantages, at least from my perspective, out in the finger – even though that is where the tendon ruptures occurred, but of the tendon ruptures in the studies all incurred in injections in the same area, and that is in the 5th finger out close to the PIP joint. And that's now sort of the no-man's land for collagenase. But for me, because collagenase doesn't affect the nerves, it doesn't digest the basement membranes, they're a different collagen—I think the safety factor in my hands at least for PIP cords for a minimally invasive technique is in favor of collagenase. Others who are more skillful with a needle and have greater experience, I suspect that they can do this just as safely.

Dr. Benhaim: One last question, if I could. I think we have all had experience with patients who come into our offices with early disease and ask us if there is anything they can do to prevent further progression of their Dupuytren's contracture. Are there any things that you can recommend to your patients either now or perhaps in the future that may be able to prevent further contracture? Is there any particular role for prophylactic splinting? Saba, can you address this initially and then maybe some of the other panelists can chime in?

Ms. Kamal: Usually when a patient is referred to us for early management of Dupuytren's and there isn't any contracture/cording, just a minimal stiffness, puckering in the skin where they're lacking some function; our response used to be to just educate them and tell them as to when to approach the surgeon. But some patients who have been insistent on us doing something have actually surprised me because in addition to educating them on things to avoid—activities, and things to do—when I splinted them, in fact this has happened on several occasions where we splinted them, showed them gentle massage techniques, used modalities—within 3 or 4 visits they've actually been able to resume the activity the way they wanted to. And that was a surprise to me that I was able to make a change where I didn't think it was possible. So that was pretty interesting. So just with night splinting, gentle massage techniques and using modalities, I was able to help them.

Dr. Benhaim: Dr. Hentz, any thoughts on that?

Dr. Hentz: I don't. I know Lynn Ketchem still is an advocate and in a recent presentation he talked about what he was doing and firmly believes that if you stay after these people and inject them regularly with fairly large doses of steroids, that you can alter the progression of their disease. But as far as I know, he's the lone voice.

Dr. Benhaim: Dr. Eaton?

HAND TABLE

continued from page 16

Dr. Eaton: The experience that I have had with steroid injections for nodules I've talked about earlier, and I do think that there's a place for the patient that has a nodule or nodules in the palm not associated with contractures. And I have had the opportunity to follow up with some folks that I've treated this way who had complete resolution of their nodules lasting for a couple of years. It's something to think about. I don't think that it's a predictable thing when someone has a contracture, or when the nodules are out in the fingers. As far as splinting, there's a very interesting presentation by Meinel from Germany, using a silicone rubber surface on the splint. He took the cue from the beneficial effect of topical silicone on hypertrophic burn scars, of which there's a fair bit of literature.

He used silicone elastomer to construct the entire palmar surface of a resting night-time extension splint. His protocol was to have folks wear a splint every night that was fashioned in their position of maximum active extension. Each month, if the active extension had improved, they would be fitted with a new splint in maximum active extension. Some of these folks would continue to have some improvement in extension over the course of months. This is after doing a needle release. Based on that experience, there may be a role of looking at this type of splint early on as maintenance, and I think that would be an interesting study to do—particularly in people who show up early but have a high diathesis score.

Dr. Benhaim: Dr. Jones, the last word.

Dr. Jones: I have tried injecting Dupuytren's nodules, but I only inject very painful nodules. I've seen modest resolution in their size,

but I've never seen them melt away completely. The only nodules I've ever seen melt away have been ones that have probably been related to some traumatic incident, but I've never seen true Dupuytren's nodules resolve completely.

There is, however, a subset of patients who are incredibly hyper-anxious about Dupuytren's disease. They've been on the Internet and they come in demanding your recommendation to prevent their condition progressing. For these patients, I've been using a silicone pad for many years, which I also use on other hand incisions. The patient just tapes it onto the surface of the nodule at night beneath a small resting extension splint. I don't think it does anything in terms of preventing the progression of the disease, but it certainly psycho-treats their anxiety!

Dr. Benhaim: Thank you all so much for participating in this panel. **H**

AAHS 2011 ANNUAL MEETING PROGRAM AT A GLANCE

AAHS 41st Annual Meeting

January 12–15, 2011

Ritz Carlton–Cancún, Cancún, Mexico

Wednesday, January 12, 2011 Specialty Day Program

6:30–7:00 am Continental Breakfast

7:00–8:00 am Instructional Courses

- 101 Fingertip and Nailbed Injuries
Chair: Mark Belsky, MD
Instructors: Kodi Azari, MD; Jennifer Green, MD; Eric S. Wroten, MD; Jeffrey Yao, MD; Georgette Fogg, OTR/L CHT
- 102 Rheumatoid Hand Reconstructions
Chair: Asif Ilyas, MD
Instructors: Brian Adams, MD; Michael Baumholtz, MD; Marco Rizzo, MD; Peter Stern, MD
- 103 How to Make an Intraoperative Video
Chair: Eric Hofmeister, MD

Instructors: Matthew Bernstein, MD; Matt Concannon, MD

- 104 Update on Kienböck's Disease
Chair: Steve McCabe, MD
Instructors: John Stanley, MBChB; Roberta Morris, OT CHT
- 105 Dupuytren's Disease Update
Chair: Jaiyoung Ryu, MD
Instructors: Kyle Bickel, MD, FACS; Philip Blazar, MD; Rod Hentz, MD; Eduardo Zancolli, MD
- 106 Reconstruction of Post Traumatic Deformities of the Finger
Chair: Randip Bindra, MD FRCS
Instructors: Gunter Germann, MD; Douglas Sammer, MD; Tsu-Min Tsai, MD; Sharon Andruskiwec, PT CHT

8:10–8:30 am President and Program Chairs Welcome
A. Lee Osterman, MD FACS, AAHS President
Jesse Jupiter MD, Program Chair
Susan Michlovitz, PT PhD CHT, Specialty Day Chair

8:30–9:30 am Panel: Should I Have Surgery? Will Therapy Help? What is the Evidence?

Moderator: Mark Baratz, MD; Gretchen Kaiser, OTD OTR/L MBA CHT
Panelists: Warren Hammert, MD DDS; Steven McCabe, MD; Stephanie Sweet, MD; Sue Blackmore, MS OTR/L CHT

9:30–10:30 am Panel: New Technologies in Upper Extremity Medical and Surgical Care—Current Perspectives

Moderators: Brian Adams, MD; Gretchen Kaiser, OTD OTR/L MBA CHT
Panelists: John Lubahn, MD; John Taras, MD; Jeffrey Yao, MD; Rebecca von der Heyde, PhD OTR/L CHT

10:30–10:50 am Coffee Break

10:50–11:30 am Panel: Troublesome Fractures in the Hand
Moderator: Jesse Jupiter, MD
Panelists: Peter Tang, MD; Georgette Fogg, OTR/L CHT; Jennifer Thompson, MPT CHT; Aviva Wolff, OTR CHT

continued on next page

Hand
Surgery
Quarterly

.....
Winter
2011

17

continued from page 17

- 11:30 am–12:00 pm** **Invited Guest Lecture (not offered for credit)**
Stephen Sullivan, MD
 “Surgical Experiences While In Haiti”
- 12:00–1:00 pm** **Panel: Cosmetic (Rejuvenation) Hand Surgery: Form versus Function**
Moderator: Laurence Glickman, MD FRCSC FACS
Panelists: Gunter Germann, MD; Randy Miller, MD; Cynthia Cooper, PT
- 5:00–6:00 pm** **“Margaritas with Mentors” Reception**
- 6:30–8:30 pm** **Welcome Reception**

Thursday, January 13

- 6:30–7:00 am** **Continental Breakfast**
- 7:00–8:00 am** **Instructional Courses (6 options)**
- 107 **Management of Injuries to the PIP Joint**
Chair: Peter Stern, MD
Instructors: Steven Haase, MD; Thomas Hunt III, MD; David Netcher, MD; Jorge Orbay, MD; Kristin Valdes, OTD OTR CHT
- 108 **La Federacion De La Mano: Hand Study Groups**
Chair: Carlos Fernandes, MD
Instructors: Scott Kozin, MD; Lynn Festa, OTR/L CHT; Joy MacDermid, BscPT PhD; Susan Michlovitz, PT PhD CHT
- 109 **Principles of Tendon Transfer**
Chair: John Lubahn, MD
Instructors: Neal Chen, MD; David Zelouf, MD; Tim Cooney; Terri Wolfe, OTR/L CHT
- 110 **Wide Awake Hand Surgery**
Chair: Donald Lalonde, MD
Instructors: Sean Bidic, MD; Eric Hofmeister, MD; A. Lee Osterman, MD FACS; Susan Kean, PT CHT
- 111 **Fractures of the Scaphoid: Pitfalls and Pearls**
Chair: Stephanie Sweet, MD
Instructors: Sanjay Desai, MD; John Drevoniany, MD; William Geissler, MD; Hervey Kimball, MD; Peter Murray, MD; Paul Brach, MS PT CHT



- 112 **Fracture Dislocations about the Elbow**
Chair: David Ring, MD
Instructors: Brent Bamberger, MD; Jose Ortiz, MD; Jaiyoung Ryu, MD; Lawrence Weiss, MD; Carol Page, PT DPT CHT
- 8:00–8:15 am** **Presidential Welcome**
A. Lee Osterman, MD FACS
- 8:15–8:45 am** **Obama in the OR**
Moderator: Mark Rekant, MD
Speaker: Andrew Gurman, MD
- 8:45–9:30 am** **Panel A: New Flaps for Hand Surgery (New Workhorse Flaps for the Hand)**
Moderator: James Chang, MD
Panelists: Allan Bishop, MD; Jeff Friedrich, MD; William Pederson, MD; Paula Galaviz, OT
- Panel B: Flexor Tendon Injuries—Master Techniques**
Moderator: TBD
Panelists: Donald Lalonde, MD; John Taras, MD; Rebecca von der Heyde, PhD OTR/L CHT
- 9:30–10:30 am** **Scientific Paper Sessions A & B**
Session A Moderators: David Bozentka, MD; W.P. Andrew Lee, MD
Session B Moderator: Michael Neumeister, MD
- 10:30–10:55 am** **Coffee Break**

- 11:00–11:30 am** **Presidential Address**
 “Collegiality: The Art of the Handshake”
A. Lee Osterman, MD FACS
- 11:40 am–12:30 pm** **Invited Guest Lecture Aron Ralston**
 Adventurer and author of *Between a Rock and a Hard Place* (not offered for credit)
- 12:30–1:30 pm** **Lunch with Exhibitors**

Friday, January 14

- 6:30–7:00 am** **Continental Breakfast**
- 7:00–8:00 am** **Instructional Courses (6 options)**
- 113 **Update on Congenital Deformities - Controversies**
Chair: Scott Kozin, MD
Instructors: William Cooney, MD; Neil Ford Jones, MD; Terry Light, MD
- 114 **Reconstruction of Malunion of the Distal Radius**
Chair: David Bozentka, MD
Instructors: Philip Blazar, MD; Jesse Jupiter, MD; Andrew Koman, MD; Kristin Valdes, OTD OTR CHT
- 115 **CMC Arthritis Open and Arthroscopic Treatment**
Chair: Mark Rekant, MD
Instructors: Alejandro Badiá, MD; Eduardo Zancolli, MD; Tandra Marik, OTD OTR/L CHT

Hand Surgery Quarterly

Winter 2011

18

continued on next page

continued from page 18

- 116 Complex Hand Fractures and Dislocations in Contact Athletes
Chair: Michael Hayton, MD
Instructors: Thomas Graham, MD; Steven Margles, MD; Chaitanya Mudgal, MD; Aviva Wolff, OTR CHT
- 117 Reconstruction of the Burned Hand
Chair: Keith Brandt, MD
Instructors: Michael Neumeister, MD; Roger Simpson, MD; Jonathan Winograd, MD; Ted Chapman, MIL USA, MEDCOM, CRDAMC
- 118 Challenges of Orthotic Selection
Chair: Rebecca von der Hyde, PhD OTR/L CHT
Instructors: Mark Rekant, MD; Jerry Coverdale, OT, CHT; Lynn Festa, OTR/L CHT
- 8:00–8:10 am **Welcome**
- 8:10–8:40 am **Panel: Innovative Hand Surgery—An International Perspective**
Moderators: A. Lee Osterman, MD FACS; Aviva Wolff, OTR CHT
Panelists: Carlos Fernandes, MD; Alexandru Georgescu, MD; Pak Cheong Ho, MD; John Stanley, MBChB; Eduardo Zancolli, MD
- 8:40–8:55 am **Debate: Is the Negative Pressure Wound Dressing a Panacea or Device of the Devil?**
Moderator: Randip Bindra, MD FRCS
Debaters: Andrew Koman, MD; Jonathan Winograd, MD
- 8:55–9:15 am **Debate: Locked Distal Radius Plate—Holy Grail or Fool's Gold?**
Moderator: Daniel Nagle, MD
Debaters: Michael Bednar, MD; Jorge Orbay, MD
- 9:15–10:15 am **Scientific Paper Sessions A & B**
Session A Moderators: David Ring, MD; Jonathan Winograd, MD
Session B Moderators: Warren Hammert, MD; Gretchen Kaiser, OTD OTR/L MBA CHT

- 10:15–10:30 am **Break**
- 10:30–11 am **Scientific Paper Sessions A & B**
Session A Moderators: Renata Weber, MD; Sue Michlovitz, PT PhD CHT
Session B Moderators: Peter Murray, MD; Joy MacDermid, BScPT PhD
- 11–11:45 am **Joint Concurrent AAHS/ASPN Panel: Assessment and Management of the Mangled Hand**
Moderator: Jesse Jupiter, MD
Panelists: Neil Ford Jones, MD; Rajan Gupta, MD; L. Scott Levin, MD; William Pederson, MD; Luis Scheker, MD
- Joint Concurrent AAHS/ASPN Panel: Failed Nerve Decompression—Now What?**
Moderator: Allen Van Beek, MD
Panelists: Allan Belzberg, MD; Tsu-Min Tsai, MD
- 11:45 am–12:30 pm **Danyo Lecture**
Moderator: A. Lee Osterman, MD FACS

- 12:30–1:30 pm **Annual Business Meeting (AAHS Members Only)**
- 1:30–5:50 pm **Comprehensive Hand Surgery Review Course**
Chair: Peter Murray, MD
For information on HRC sessions, titles, instructors, and the presentation details, go to www.handsurgery.org.
- 3:30–3:50 pm **Break**
- 7:00–10:00 pm **AAHS Salsa Dinner Dance**

**Saturday, January 15
AAHS/ASPN/ASRM Combined Day**

- 6:30–8:00 am **Breakfast with Exhibitors**
- 7:00–8:00 am **AAHS/ASPN/ASRM Instructional Courses**
- 201 Controversies in the Management of Nerve Compression in the Upper Extremity
Chair: Thomas Hughes, MD
Instructors: Tyson Cobb, MD; Neil Ford Jones, MD; John Lubahn, MD; Mary Nordlie, MS OTR CHT

- 202 Reconstruction of Acute and Chronic Scapholunate Ligament Injuries—How I Treat
Chair: Mark Rekant, MD
Instructors: Steven Moran, MD; Peter Stern, MD; Jennifer Thompson, MPT CHT
- 203 Cortical Plasticity and Changes with Nerve Injury
Chair: Dimitri Anastakis, MD
Instructors: Martijn Malessy, MD PhD
- 204 Adult Brachial Plexus Lesions
Chair: Allan Belzberg, MD
Instructors: Michael Dorsi, MD; Thomas Tung, MD; Justin Brown, MD
- 205 Monitoring Technologies for Flaps and Replants
Chair: William Swartz, MD
Instructors: Darrell Brooks, MD; Alex Keller, MD; Hakim Said, MD
- 206 Innovation in Free Flap Surgery
Chair: Geoff Gurtner, MD
Instructors: David Brown, MD; Paul Cederna MD
- 8:15–8:30 am **AAHS/ASPN/ASRM Presidents' Welcome**
A. Lee Osterman, MD FACS, AAHS President
Paul S. Cederna, MD, ASPN President
Peter C. Neligan, MD, ASRM President

- 8:30–9:30 am **AAHS/ASPN/ASRM Panel: Robotic Surgery**
Moderators: Jesse Selber, MD
Panelists: Michael Bednar, MD; Philippe Liverneaux, MD; Sijo Parekattil, MD
- 9:30–10:00 am **Coffee Break with Exhibitors**
- 10:00–11:00 am **Joint Presidential Keynote Lecture Bob Woodruff**
(not offered for credit)

- 11:00 am–12:00 pm **AAHS/ASPN/ASRM Joint Outstanding Papers**

H

Hand Surgery Quarterly

Winter 2011

AAHS Mentoring Program Volunteers

Below is a list of AAHS members who have generously offered to teach their expertise in specific areas, letting our members continue to learn the way we were taught, as residents and fellows, in the clinic and oper-

ating room with a surgical mentor. For more information, please contact the AAHS Central Office. **H**

NAME	EMAIL	PROCEDURE(S)
R. D. Beckenbaugh, MD	beckenbaugh.robert@mayo.edu	Technique of pyrocarbon arthroplasty of the thumb carpometacarpal; and metacarpophalangeal and PIP joints of the digits
Richard Berger, MD, PhD	berger.richard@mayo.edu	Wrist surgery
Kyle Bickel, MD	kbickel@sthand.com	Vascularized bone graft reconstruction for carpal pathology; complex fracture management in the hand and wrist; and arthroscopic wrist ganglion excision
Allen Bishop, MD	bishop.allen@mayo.edu	Brachial plexus reconstruction; carpal vascularized bone grafts; and microvascular free tissue transfers
James Chang, MD	changhand@aol.com	Dupuytren's Contracture; thumb reconstruction; flexor tendon surgery; trapezial excision arthroplasty; and medial epicondylectomy
Kevin Chung, MD	kechung@med.umich.edu	Rheumatoid and congenital
Tyson Cobb, MD	tycobb@mchsi.com	Endoscopic Cubital Tunnel Release
E. Gene Deune, MD	egdeune@jhmi.edu	Congenital hand anomalies; upper and lower extremity reconstruction for deficits due to trauma; cancer resection; and neurological disorders (i.e. brachial plexus)
Scott H. Kozin, MD	SKOZIN@shrinenet.org	Pediatrics
Don Lalonde, MD	drdonlalonde@nb.aibn.com	Wide awake approach to hand surgery
W. P. Andrew Lee, MD	leewp@upmc.edu	Post traumatic hand reconstruction; mini incision carpal tunnel release
Susan Mackinnon, MD	mackinnons@wustl.edu	Ulnar nerve surgery
Nash Naam, MD	drnaam@handdocs.com	SLAC wrist reconstruction; vascularized bone graft in treating scaphoid nonunions; ulnar shortening & radial shortening; PIP & MP joint arthroplasty; LRTI; arthroscopy of the CMC joint of the thumb
Daniel J. Nagle, MD	DOGIEN@aol.com	Wrist arthroscopy; endoscopic carpal tunnel release
Michael Neumeister, MD	mneumeister@siumed.edu	Basilar joint arthroplasty; peripheral nerve decompression
Jorge Orbay, MD	jlorbay@aol.com	Wrist fractures
A. Lee Osterman, MD	loster51@bellatlantic.net	Advanced wrist arthroscopy and small joint arthroscopy. Can also mentor a topic such as DRUJ problems, or wrist fracture.
Julian J. Pribaz, MD	jpribaz@partners.org	Soft tissue reconstruction; microsurgical reconstruction; spare parts surgery and extremity reconstruction
Michael Raab, MD	mikeraab1@earthlink.net	Corrective osteotomy (volar or dorsal) of distal radius malunion with iliac crest bone grafting
Jaiyoung Ryu	jryu@adelphia.net	Wrist reconstruction; distal radius fracture; and scaphoid fracture/nonunion
David Slutsky, MD	d-slutsky@msn.com	Use of volar wrist portals for wrist arthroscopy and arthroscopic repair of dorsal radiocarpal ligament tears; nonbridging external fixation of intra-articular distal radius fractures; nerve conduction studies for hand surgeons; and comparison of NCS and PSSD for the diagnosis of CTS
William Swartz, MD	william.swartz@verizon.net	Tendon transfer and ulnar nerve
Thomas Tung, MD	tungt@wustl.edu	Brachial plexus and nerve transfers
Joseph Upton, MD	jupton3@earthlink.net	Congenital hand surgery
Elvin Zook, MD	ezook@siumed.edu	Fingertip reconstruction