

# HAND SURGERY

## QUARTERLY



## Endowment Sets Goal

### A Million Dollars! Can We Do It? Yes!

**T**he endowment will grow by some \$50,000 per year alone by the continued giving of so many members of the Association. That \$250,000 added to our current assets of \$250,000 will give \$500,000 total. Wise investing for growth with the effect of compounding, and a bequest or two, will allow us to reach our million dollar goal.

### What Can Be Done with a Million Dollars?

The Endowment will be able to contribute between \$50,000

and \$100,000 every year to the Association's educational programs. This will make it possible to hold the costs down, so that more members will be able to come to the annual meeting. And by 2005, the new steps to increase Internet applications will be in full swing. The Endowment can contribute to this new tool for learning.

### What is Our Vision?

We have a vision for a vital, growing, interactive, educational AAHS. The potential is unlimited. Help us meet this goal. Contribute. Support. Bequeath. Help. Use all these action verbs to see this goal become a reality. **Endowment \$1M by 2005!** **H**

*Robert R. Schenck, MD  
President, The Hand Surgery  
Endowment*

## The Endowment: How Have We Done?

- After four years, the Hand Surgery Endowment has reached over a quarter of a million dollars. To reach that mark, over five hundred individuals have given gifts ranging from \$150 to more than \$20,000.
- Through wise investing alone, assets grew twenty per cent in the last year. They have reached the quarter million dollar milestone.
- Administrative costs have been held to less than ten percent of gifts received during the year.
- The endowment has underwritten, in whole or in part, the following projects:
  - Resident Essay and Poster Awards
  - President's Invited Lecturer
  - Spanish Translation at the Annual Meeting
  - Vargas Hand Therapist Award
  - Hand Therapy Pre-Conference Seminar.

**\$1M**  
**BY 2005**

## New Editor Calls for Your Support

**W**ith this edition of the AAHS Newsletter, Jim Hoehn steps down and I assume the role of editor. This is certainly a daunting proposition; Jim has done an outstanding job in creating and nurturing this newsletter, which I believe is the most informative hand surgery newsletter available. My purpose as the new Editor of this Newsletter is to keep it timely, informative, and useful. I will focus on that purpose, but I need your help.

PETER C. AMADIO, MD

During my tenure, I expect that new technologies will alter the form, but hopefully not the quality, that you have come to expect under Jim's able leadership. Fortunately, Anne Behrens remains as our talented managing editor. Simply put, she is the best. As with any voluntary effort, I will need the help of energetic volunteers to help carry out this purpose. I do hope that you will agree to contribute to the Newsletter with your ideas, letters, and perhaps even feature articles. Please feel free to contact me with your suggestions to improve the Newsletter at any time. And we will call on you, as we plan to spotlight the diversity of our membership with member profiles. Finally, we are planning some exciting new "Around the Hand Table" discussions on controversial topics of current interest. Thanks for being a part of AAHS, and have a great summer. **H**

## 2000 Membership Roster

**T**he American Association for Hand Surgery will not be producing a hard copy roster for 2000. An updated roster can be found on our Web site [www.handsurgery.org](http://www.handsurgery.org). The Board members of the AAHS felt that this would be a more efficient way to circulate our membership contact information.

The membership directory located on the web site is continually updated and is only available to members of the American Association for Hand Surgery. Soon you will be receiving a password and ID number for access to this information. If you would like to receive a hard copy printout of the membership directory please contact the Central Office at (312) 236-3307. We hope you find this a more efficient way to communicate amongst your fellow members. **H**

## Amadio Named AAHS 2000 Clinician/Teacher of the Year

**T**he 7th Annual AAHS Clinician/Teacher of the Year Award was presented at this year's annual meeting in South Miami Beach to Peter C. Amadio, MD. Dr. Amadio graduated from Pennsylvania State University and from Jefferson Medical College with his doctorate in medicine. After finishing an orthopedic surgery residency at the Harvard Combined Orthopedic Program, Dr. Amadio completed a fellowship in hand surgery at Jefferson Medical College. He accepted a clinical assistant professorship in Orthopedic Surgery at SUNY at Stony Brook prior to being appointed senior associate consultant in orthopedic clinics, in 1983, at the Mayo Clinic. He has

remained at the Mayo Medical School and was appointed full Professor of Orthopedic Surgery in 1993. Dr. Amadio has been intensely involved in clinical and basic research, publishing approximately 100 articles in peer review journals and 40 book chapters. His presentations in regional, national and international venues are almost innumerable. In addition to this intense level of involvement, Dr. Amadio has also participated in many instructional courses, including his untiring willingness to serve as Chair or Co-chair of Educational Programs.

In addition to his outstanding contributions as a clinician/teacher in hand surgery, Dr. Amadio has also provided his political and

administrative expertise to numerous professional organizations, including extended service on the Board of Directors and on the Executive Committee of AAHS. Following his presidency in 1998-1999, Dr. Amadio has continued to give generously of his time and experience. The American Association for Hand Surgery takes great pride in presenting the Clinician of the Year Award for 2000 to Dr. Amadio, in appreciation of his exemplary service as a leader, friend, colleague and exceptional clinician/teacher.

*William F. Blair, MD*  
AAHS President

## Planning for the 2001 Annual Meeting in San Diego Continues

Spring of 2000 has been a very busy time for the AAHS in our Central Office. A variety of administrative activities are ongoing to further strengthen and improve our organization. As I explained in the Spring 2000 *HSQ*, these activities are directed by our Strategic Plan. We are moving forward in our Ad Hoc Committees to reorganize our committee structure, expand Internet applications for members and the public, and to enhance ser-

vices for our international members and visitors. We have also continued in other directions that I personally thought were important to our organization. Although the AAHS has responsibly managed our financial reserves in past years, we have an opportunity to stabilize our investment practices and at the same time improve our returns on reserves. The intent is to ultimately increase the amount of resources available to serve our membership. In terms of administrative structure and practice our organization has evolved considerably with the last few years. In response, Dr. Nash Naam is comprehensively reviewing and revising our Policy and Procedure guidelines prior to our Mid-Year Board Meeting.

Among our organization's goals has been the advancement and strengthening of our relationships to other professional organizations, and most specifically to the American Society for Surgery of the Hand. I am increasingly optimistic that these efforts will be successful and fruitful. Conferencing among the president and president-elects continued at our last annual meeting. Our organizations have agreed to continue regular conferencing, perhaps in the context of a hand care professional oversight organization, including not only leadership from AAHS and ASSH but also representatives from AAHS affiliates, ASHT and possibly representation from Hand Care Professionals. I am supportive of this direction, believing that it will better position us to provide comprehensive education for the members of our respective organizations, and it will also present added opportunities for public education in the operative and nonoperative care of upper extremity disorders.

The emphasis, though, during the spring of 2000, for myself and the Central Office, has been our 2001 Annual Meeting in San Diego.

The facility at the Loews is ideal for our organization's annual meeting. We will occupy the entire hotel, with full access to the conferencing space, recreational facilities and equipment, and restaurants. It is a comfortable, convenient, and relatively new resort, ideal for educational programming, relaxing, and family vacationing.

The program this year includes a combined meeting with both the American Society for Reconstructive Microsurgery and Peripheral Nerve Surgery. The presidents and program chairs of all three organizations have been working effectively together to develop an integrated program. We have worked diligently with the concept of optimizing educational value for our respective members. My impression, after both visiting the Loews and reviewing proposed programs, is that our facility may be ideal for making this type of an integrated meeting structure happen.

No one has been working harder through the spring 2000 than our program chair, Dr. Mark Baratz. He and his committee are not only meeting the challenge of integrating our content with that of two other organizations, but they have also explored some novel programming ideas. In response to member survey-expressed preferences for increased clinical course content, the programming will include more panels and instructional courses. Tentatively the program committee is looking at a session dedicated to resident participation, including resident papers, panels, and moderators.

I am personally excited about our proposed Keynote and Presidential Invited Speakers for the Annual Meeting and will provide further updates in the next *Hand Surgery Quarterly*. **H**



WILLIAM F. BLAIR,  
MD

### HAND SURGERY QUARTERLY

#### President

William F. Blair, MD

#### Editor

Peter C. Amadio, MD

#### Executive Director

Laura Downes Leeper, CAE

#### Managing Editor

Anne B. Behrens

*Hand Surgery Quarterly* is a publication of The American Association for Hand Surgery and is published strictly for the members of AAHS. This publication is designed as a forum for open discussion and debate among the AAHS membership. Opinions discussed are those of the authors or speakers and are not necessarily the position, posture or stance of the Association.

Copyright © 2000, The American Association for Hand Surgery. All rights reserved. No portion of this newsletter may be printed without express written permission from the publisher, 20 N. Michigan Avenue, Suite 700, Chicago, IL 60602, 312-236-3307.

# AAHS Directors at Large

## William C. Lineaweaver, MD

**W**illiam C. Lineaweaver, MD is an alumnus of Davidson College and the University of Florida's College of Medicine. He completed general surgery training at the University of Virginia and the University of Florida;



plastic surgery residency at the University of California at San Francisco; and a hand and microsurgery fellowship at the Davies Medical Center in San Francisco.

Professionally, Dr. Lineaweaver was in private practice in San Francisco from 1986 to 1992 and subsequently on the faculty of Stanford University from 1992 to 1999. Currently, he is a Professor and Director of Microsurgery and Research in the Division of Plastic Surgery at the University of Mississippi.

A member of the AAHS since 1993, Dr. Lineaweaver has served as a member and chairperson of the Grants Committee. His other professional associations include Fellowship in the American College of Surgeons and memberships in the American Society for Reconstructive Microsurgery and the American Association for Plastic Surgery.

## Dan Nagle, MD

**D**an Nagle, MD received his undergraduate degree from Colgate University and graduated from the University of Brussels Medical School with honors in 1978. After completing his internship at the Loyola Affiliated



Hospitals in Chicago, he joined the Northwestern University Orthopaedic Residency Program. Four years later he became a Christine Kleinert Fellow in hand and microsurgery. At the end of his fellowship he joined the hand surgery practice of doctors Bell, Stromberg, and Harris, the continuation of the Chicago Hand School founded by Kanavel, Koch, Mason and Allen. Dr. Nagle is currently an associate professor of clinical orthopedics at Northwestern University Medical School.

Dr. Nagle has authored many scientific papers and chapters and has given numerous lectures, presentations and courses.

Dr. Nagle has been active in both local and national hand surgery, orthopedic and microsurgical societies. He has served as President of the Chicago Society for Surgery of the Hand. He is the Immediate Past President of the American Society for Reconstructive Microsurgery. He is currently serving on the AAOS Health Care Finance Committee and is the Chairman of the ASSH CPT/RUC and Government Affairs Committees. He is a member of the Hand/Wrist Subcommittee of the AANA Orthopaedic Learning Center Committee. Dr. Nagle joined the AAHS in 1995 and was elected to the Board of Directors as the Junior Director at Large in 1999.

## A. Lee Osterman, MD

**D**r. A. Lee Osterman received his BA from Yale University where he graduated Summa Cum



Laude and he received his MD from the University of Pennsylvania. He interned in surgery at Mt. Sinai Hospital and Medical School in

New York. His orthopaedic residency was at the University of Pennsylvania where he was a fellow in hand surgery as well as a microvascular surgery fellow at Duke University. He is Board Certified in orthopaedic surgery and has added qualifications for hand surgery. Dr. Osterman was an Associate Professor of Orthopaedic Surgery at the Hospital of the University of Pennsylvania for a number of years before becoming a full Professor of Orthopaedic and Hand Surgery at The Thomas Jefferson Hospital where he specializes in upper extremity and hand surgery and rehabilitation.

At present, Dr. Osterman is Director of the Philadelphia Hand Center, a seven member private university practice with five fellows per year. He is also the current President of the Eastern Orthopaedic Association and has served on numerous committees for the ASSH, AAHS, AAOS, and ASRM.

He has authored more than 200 publications and is currently the Editor of *The Atlas of Hand Surgery*. His research interests include small joint arthroscopy, peripheral nerve regeneration, control of soft tissue scar, and ligament reconstruction.



## Robert L. Walton, MD, FACS

Robert L. Walton, MD, FACS is Professor of Surgery and Chief of the Section of Plastic Surgery



at the University of Chicago, Chicago, Illinois. Dr. Walton is a native of Lawrence, Kansas and an alumnus of the University

of Kansas and the University of Kansas School of Medicine. Dr. Walton received his training in surgery and plastic surgery at Johns Hopkins and Yale-New Haven Hospitals. He served as a hand fellow under Dr. H. Kirk Watson in

Hartford, Connecticut. He began his academic career at the University of California San Francisco as Chief of Plastic Surgery at the San Francisco General Hospital. In 1983 Dr. Walton was appointed Chairman of the Division of Plastic Surgery at the University of Massachusetts Medical Center, a position he held for 10 years. In 1994 he assumed his current position as the Plastic Surgery Section Chief and Training Program Director at the University of Chicago. Dr. Walton has authored over 150 scientific articles and currently serves as Associate Editor of the *Journals of Hand Surgery and Plastic and Reconstructive Surgery*. His research interests have focused on tissue engineering and reconstructive microsurgery.


Dr. Walton is Founder of Proyecto MIRA (1987), a non-profit

organization dedicated to the treatment of indigent children of Puerto Rico suffering from acquired or congenital deformities of the Head and Neck and upper extremity. Nationally, Dr. Walton is active in numerous surgical organizations, including the ACS (Advisory Council and Scientific Program Representative for Plastic Surgery), the AAPS (Strategic Planning Committee), the ASRM (Treasurer and Bylaws Committee Chairman), and the ASPS (PSEF Representative to the Scientific Program Committee). Since joining AAHS in 1980, Dr. Walton has served on the Education Committee, Scientific Program Chair, Director, Parliamentarian, Chairman Bylaws Committee, Ethics Committee Chairman, AAHS representative to ASPS Board of Directors, and is currently Senior Director. **H**

## assi Classic Forceps

• Exceptional design and uniform weight distribution yield a perfect balance.


• Enduring performance – made of the finest surgical steel for durability.



ASSI®-230  
18cm long, straight



ASSI®-231  
18cm long, curved



ASSI®-233  
18cm long, straight, Vickers micro ring tip 1mm dia.



ASSI®-1166  
15cm long, Pliers tip 0.3mm dia.



ASSI®-1164  
15cm long, straight w/1x2 teeth

**assi**

To do the best work, choose the best tools.™

accurate surgical & scientific instruments corporation

1.800.645.3569 (New York) 1.800.255.9378 (West Coast)

FAX: 1.516.997.4948 • E-MAIL: assi@accuratesurgical.com • INTERNET: www.accuratesurgical.com

Hand Surgery  
Quarterly

Summer  
2000

## Introducing Hand Therapy to Egypt

Vargas Hand Therapy  
International Teaching Award  
1999: Cairo, Egypt

By Katherine Schofield, OTR/L, CHT

**C**airo, Egypt: a vibrant city of over 18 million, home of the monumental pyramids of Giza, a wealth of history that attests to the presence of a higher form of civilization. A city within a country of 65 million where no hand therapy exists.

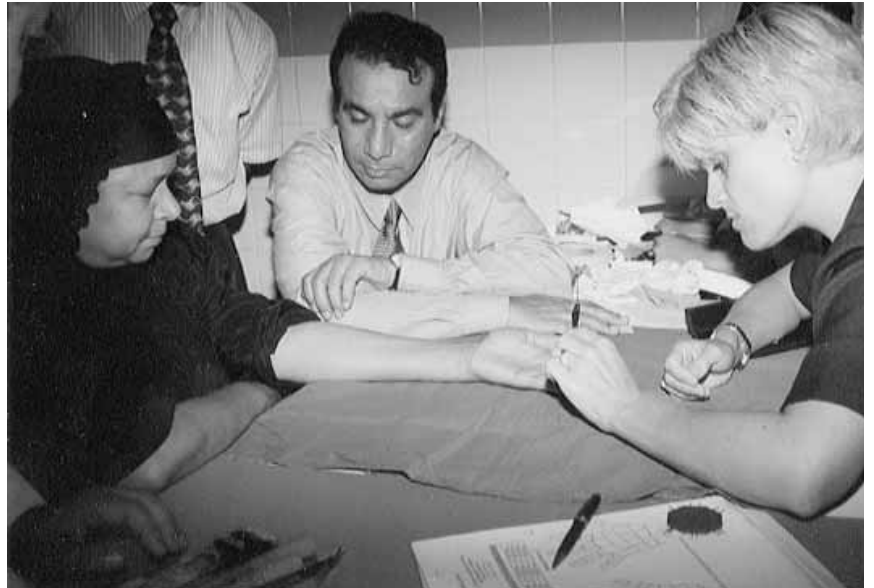Myself, along with three hand surgeons, introduced this specialty to plastic and orthopedic surgeons and physical therapists in this country over a three week period. Our adventure began officially June 12, when we all arrived on Egyptian soil, but the experience began to take shape long before that date. Prior to our arrival in Cairo, Dr. Nash Naam collaborated extensively with the Egyptian government and fellow surgeons in Cairo to organize our itinerary. We were considered formal guests of the government and were subsequently granted exceptional personal service while in Cairo which undoubtedly allowed us to accomplish much more than if we were left to our own devices.

Our arrival at the Cairo airport came at last, where we were greeted by two Egyptian hand surgeons whom we were to work closely with during our entire stay. We were escorted by our personal driver to our hotel which was adjacent to the Nile river in the heart of Cairo. Being in this incredible city places new meaning on the word TRAFFIC!!! There appears to be no

order to the flow of cars, buses, taxis, bicycles on the streets but everyone gets to their destination... eventually. The streets are filled with pedestrians, street vendors, cars, bicycles and noise. It was quite an experience just getting to

plaster. One to one contact between therapist and patient does not exist.

Our schedule was a busy one. We began with a three day structured course in the treatment of the hand and UE where surgical and therapeutic management principles



Therapist Katherine Schofield performs a sensory evaluation in the therapy unit with Dr. Safoury observing.

our hotel.

A visit to the infamous pyramids of Giza preceded our teaching itinerary where we walked inside these ancient burial grounds, marveled at the architecture and rode our first camels!! Then it was off to the El Hehel Hospital in Cairo where the first "hand unit" was due to open during our stay. The unit consisted of one exam room, x-ray facilities, a therapy room, space for completion of EMGs and a waiting room/reception area. It is the first of it's kind in Egypt; hand surgery as a specialty is not common. Most surgery, up until recently, has been done by plastic and orthopedic surgeons who do not devote all of their time to the treatment of the hand and UE. Hand therapy is non-existent as a specialty. Therapy is typically done by the surgeons themselves in the form of patient education; splinting is done with

were presented. We covered such topics as tendon repair, arthritis, RSD, fractures, splinting and nail bed injuries. The course and it's content were extremely well received by the audience of approximately 200 orthopedic surgeons. Dr. Fahamy, one of Egypt's first hand surgeons and thus honored by the International Society for Surgery of the Hand, presented issues that currently face surgeons in this country. What an honor to have him there with us!!

The next item on our agenda were lectures at Alexandria School of Medicine where we again presented on various topics in hand surgery and therapy to plastic surgery residents and nursing students at the university. We were almost late for our engagement here as we experienced an interesting delay on our way to this seaside city three hours from Cairo. We



were stopped along the way by government officials/security and from that point onward had our own escorts into the city. This consisted of no less than five armed guards in a vehicle in front and behind our van. Needless to say we arrived safe and sound but one hour late!!! While in and around Alexandria we had opportunity to visit with the chief plastic surgeon at the university and enjoy a few hours at his summer home along the coast of the Mediterranean. Beautiful and very peaceful, sitting on the beach and observing life here emphasizes the diversity and cultural differences that exist in our world. Women routinely would enjoy the waters of the Mediterranean fully clothed with veils, long sleeves, garments, gloves, etc. while men and children wore bathing suits or other summer type attire.

Upon our return to Cairo once again the moment had arrived for the opening day of the hand unit. The event was televised throughout Egypt and we were interviewed and photographed extensively by the media. The Minister of Health was present along with other government officials where the need for hand and UE services was emphasized to the public. Again, it was quite an honor to have the opportunity to participate in and influence such an important event. We also had opportunity to meet personally with the Minister and discuss our purpose and the need for hand surgery and therapy specialization in Egyptian health care. We appeared on "Good Morning Egypt", a morning program similar to Good Morning America here in the US where we again discussed our purpose, hand surgery and hand therapy issues currently facing Egypt and the need for development of such.

Our last formal engagement was with the Physical Therapy Institute of Cairo where we lectured on vari-

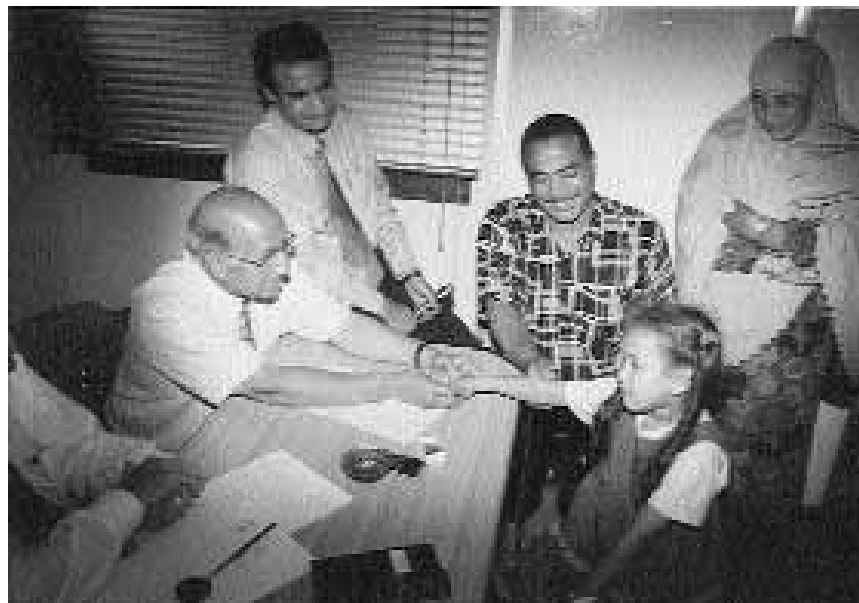ous topics of hand surgery and therapy. Therapeutic management issues were emphasized. I also spent time discussing ASHT and AAHS, their roles in the continued development of hand therapy and surgery and hand therapy certification. I received very positive feedback from the audience and hopefully some of these therapists will contact ASHT in the future.

Throughout our stay in Cairo we spent time at the hospital with two aspiring hand surgeons, Dr. Yasser Safoury and Dr. Akeem Abdulla. These two surgeons were instrumental in the development of the hand unit at their hospital and they dedicate 100% of their practice to hand surgery. We participated in patient evaluation, surgery and discussed treatment options with the staff. I completed a splinting workshop and demonstrated various treatment strategies and evaluation techniques to the physical therapist and other staff members. It was incredibly enriching to participate in direct patient care where we had opportunity to interact with the patients and their families. We observed many cases of obstetrical palsy, compressive neuropathies

and late effects of trauma such as joint contractures, hypertrophic scarring and loss of function. We had several requests from patients and their families for "new arms". They had heard that the "American doctors" were in town and it is in America where they transplant arms and hands!!

As busy as we all were during our three week stay, we managed to have ample opportunity to see and experience the sights and sounds of Cairo, enjoy local hospitality in people's homes and tour the Nile on a three day cruise where we visited the infamous temples and ruins of ancient Egypt. The time spent in this wonderful country was so enriching and productive thanks to the unending efforts of Dr. Nash Naam. A native of Cairo, a gentle, caring, loving man who demonstrates his passion and love for hand surgery and therapy by giving so much of himself back to his country. He has been instrumental in the development of hand surgery in Egypt and continues to be diligent in promoting this specialty. He returns to Egypt regularly where he actively participates in lectures and

*continued on page 8*



Dr. Nash Naam enjoying time with a patient and her family.

## THErapy CORNER

*continued from page 7*

courses on hand surgery. Drs. Safoury and Abdulla have visited his practice in Effingham, IL where they spent 6 months with him and his staff further developing their skills.

Let me not forget the efforts of two other wonderful surgeons, Dr. Leonard Bodell and Dr. Richard Brown who accompanied us on our trip. They graciously volunteered their time to accompany us on our journey and their presence and contributions were simply immeasurable. I have been fortunate to



**The splinting workshop proved to be very valuable to both the physicians and therapists.**

work with Dr. Bodell in a private practice setting for nearly 10 years; the opportunity to share our experiences and expertise as a team was extremely valuable to our colleagues and friends in Cairo.

Walking away from such an experience leaves behind so many wonderful memories and opens up and builds on future hopes and dreams. I sincerely hope that we may return to Egypt over the next few years to develop our ideas further and see some form of hand therapy in practice. I also hope to participate in the education of future hand therapists by sponsoring a student to come to this country where they may take back the core, necessary skills needed to foster the growth of this profession in Egypt. **H**

## HAND THERAPY PROFILE

### Colette Jewell, OTR, CHT



**COLETTE JEWELL, OTR, CHT**

**Personal:** I was raised in Denver but have spent the past 15 years Visalia which is an agricultural community in Central California. After work I switch to the “second shift” which consists of raising two daughters and a son. I enjoy spending time with my family, soccer games, movies, and mountain activities like hiking and skiing.

**Education:** I graduated from Colorado State University in 1977 with a BS in Occupational Therapy. I received my hand therapy certification in 1991.

**Employer:** I manage the outpatient hand therapy clinic of a 500-bed hospital, Kaweah Delta Health Care District (the only regional care facility between Fresno and Bakersfield).

**AAHS Involvement:** I originally became involved with AAHS in 1987 when I was in private practice. I found that I enjoyed the meetings as well as their location and the way therapists were included in the organization. Since then I have served as the chair for the hand therapy committee, received the 1997 Vargas Hand Therapy Teaching Award, which involved traveling to Kenya with Dr. Paul Weeks. I currently serve on the Vargas committee.

**Best Part of My Job:** Guess it sounds kind of “Hallmarky”, but it’s the people; the ones I treat and the ones with whom I work. I have learned so much about the things that really matter in life from my patients. When they come to me for therapy, with mangled hands and feeling hopeless, I get great satisfaction from being a part of their journey towards physical and emotional healing.

**Major Accomplishments:** Combining career and family; clinical specialties; splinting, cumulative trauma, arthritis, wound care.

**Greatest Challenge:** Remembering to treat the patient as a person, regardless of insurance, hectic schedules, understaffing, or personal problems.

**Three Words That Describe Me:** Principled, tenacious, spontaneous.

**H**



# Fracture Management

*Managing a fracture situation can be difficult, since often there are many physical—and even emotional—factors that can make a difference to the patient's outcome. The moderator for this discussion of some real life cases is **Susan Michlovitz, PhD, PT**, Associate Professor, Physical Therapy, Temple University, Philadelphia, PA. Joining her on the panel are hand surgeons **Mark Cohen, MD**, Associate Professor, Director, Hand and Elbow Program, Dept. of Orthopaedic Surgery, Rush-Presbyterian-St. Lukes Medical Center, Chicago, IL, **William M. Swartz, MD**, Associate Clinical Professor of Plastic Surgery, University of Pittsburgh School of Medicine, Pittsburgh, PA, and **Paul Zidel, MD**, Private Practice Hand Surgery, Ft. Lauderdale, FL, former Program Director, Wayne State Univ. Hand Fellowship Program, and former Chief of Plastic & Reconstructive Surgery, Detroit Receiving Hospital, Detroit, MI. Hand therapist **Paul Brach, PT, MS, CHT**, Clinical Specialist, Centers for Rehab Services, Department of Hand & Upper Extremity Rehabilitation, Pittsburgh, PA completes the panel.*

**Dr. Michlovitz:** We will discuss the management of wrist fractures using radius fracture as an example. I have chosen two different types of distal radius fracture injuries in two age groups.

The first example is that of a 22-year-old female who was in a motorcycle accident, a high energy injury. She was a passenger in the accident and the driver was killed. She sustained a distal radius fracture that was unstable and not reducible. The fracture was comminuted and intra-articular. She had open injuries to her palm and dorsal forearm. She lost a considerable amount of tissue on her dorsal forearm. She was treated with a volar plate and a bone graft. And she had a skin graft to the dorsum of her forearm. Her palmar injuries were sutured. She ended up with a neuroma of the common digital nerve to the index finger. She had delayed healing of the fracture.

When there is a comminuted intra-articular distal radius fracture going into the distal radial ulnar joint, what would your initial evaluation of that patient be in a clinical exam and what would you look for in the x-ray to guide your treatment? Dr. Zidel?

**Dr. Zidel:** There are many classifications of distal radius fractures;

Frykman, Melone AO, Mayo, Rayhack, Universal, Medoff, Fernandez, etc., which may help with understanding treatment options. It is very difficult to know the extent, though, without actually seeing the x-rays. Since it is intra-articular into not only the distal radiocarpal joint, but also the distal ulnar joint, such a high impact injury may be associated with TFCC, scapholunate and neurovascular injuries.

**Dr. Michlovitz:** As far as we are aware there is no scapholunate ligament injury and no TFC complex injury. She did have a laceration to her radial artery.

**Dr. Zidel:** It would be important to assess, in an orderly manner, the viability, stability and the associated structures, like the flexor carpi radialis, the median nerves, and the radial artery. For a high impact injury almost assuredly decompression and repair of the artery are indicated. After making sure there are no other associated local injuries, forearm compartment syndrome, systemic injuries, etc., and once everything is stabilized, the treatment is to have as best a strong, stable reduction as possible for intra-articular fractures. The standard fixation systems need to be chosen

based on the fracture pattern. There are newer systems, such as the Trimed-Medoff system, and another recent one, which I have not seen but I am told is a distal radius two-part external fixation system that does not span the radial carpal joint. In other words, it goes from the shaft of the radius to the distal aspect of the radius to support the fracture.

**Dr. Michlovitz:** Dr. Cohen? Do you have any comments on your initial management?

**Dr. Cohen:** It is important to first carefully observe the limb and wrist, looking for deformity, looking for any skin lacerations or skin punctures, which might suggest an open injury, evaluating vascularity of the hand, and checking sensation of the digits. Although this injury will require operative intervention, I think it's important not to leave the wrist deformed or subluxated, as this places additional tension on the soft-tissues. A reduction followed by application of a splint,

WE WILL DISCUSS  
THE MANAGEMENT OF  
WRIST FRACTURES  
USING DISTAL RADIUS  
FRACTURE AS AN  
EXAMPLE.

SUE MICHLOVITZ, PhD, PT

Hand Surgery  
Quarterly

.....

Summer  
2000

continued on page 10

## AROUND THE TABLE

continued from page 9

with sterile dressings applied to the wounds, would thus be appropriate while waiting to get to the operating room.

**Dr. Michlovitz:** Dr. Swartz, what would you do as far as the dorsal forearm open wound?

**Dr. Swartz:** First of all, this is not a circumstance to be managed in the emergency room. This requires getting to the operating room as soon as the appropriate radiological evaluations are carried out so you understand what the fracture requirements are going to be. Once you have reduced the fracture or dislocation, in order to take care of any impending vascular or nerve problems, you set about in an orderly fashion to do the appropriate fracture fixation and soft tissue management. I would not worry at all about the radial artery other than to control hemorrhage. Whether you repair it or not is down on the list of priorities. I

agree that once you are in the operating room and you've got debridement and irrigation under way, then decompression of the median nerve is very important. The appropriate fracture fixation depends on whether it is stable or unstable, an intra-articular fracture or displaced. Also, it is likely to require internal fixation.

**Dr. Michlovitz:** And if it's displaced, intra-articular and does not stay reduced, what type of internal fix-

ation choices would you have?

**Dr. Swartz:** The type of fixation depends on bone stock. A young person is likely to have solid bone stock. Most likely if it's not terribly comminuted and the fracture fragments are discreet, plate fixation with a T-plate placed either volar or dorsal (depending on which way it is displaced) would be my first choice. Alternately, interfragmentary screws or K-wires might be selected. The point is to get anatomic reduction of the articular surface and stable fixation. I personally prefer internal fixation with plates and screws to perhaps get earlier motion. However, my primary consideration is to get accurate anatomic alignment.

**Dr. Michlovitz:** After the emergent care, Dr. Zidel, what steps would you take from there? Let's assume there was a dorsal T-plate placed as well as a split-thickness skin graft to the dorsum of her forearm. There was injury to the common digital nerve of the index finger that was not addressed, which ultimately ended up in an annoying neuroma.

**Dr. Zidel:** The advantage of this early fixation is the ability to reestablish motion, decrease swelling, and increase function at an earlier stage. In general, I would begin early motion as soon as possible. In this particular case it probably would not be for nearly a week. I would assess her skin graft at two days and then at five days and begin motion at that point. The key is since it is a high-impact injury, she is at risk for skin graft loss. That and the risk of occult injuries may modify my early motion regimen.

**Dr. Michlovitz:** How about you, Dr. Cohen?

**Dr. Cohen:** This patient would probably be admitted to the hospital postoperatively. We have found it very helpful to suspend the arm from an intravenous pole with the elbow supported (if there is not a concern of a compartment syndrome). This seems effective in

diminishing swelling to the hand. I would like to leave the digits free and start finger motion as soon as possible. She has already suffered an initial soft-tissue injury, followed by surgical trauma with placement of a relatively high-profile dorsal plate. The skin graft in my mind is of lower priority. She can always have another skin graft, but if her fingers get stiff she may never recover adequate hand function. With adequate pain control medication, it is probably not a bad idea to have the therapist visit her on postoperative day one to begin some edema control modalities, such as finger socks, while encouraging active and some gentle passive digital motion. Wrist motion to me is secondary as well. The fingers have priority in this setting. I would like not to lose her hand just because she fractured her wrist.

**Dr. Michlovitz:** Mr. Brach, if you are the therapist sent to visit the patient on postoperative day one, what would you add to her care?

**Mr. Brach:** I would assess the status of the hand, start range of motion of the fingers, as well as address edema control as soon as possible to prevent any further complications. Also, instruct the patient on a home exercise program in digital range of motion and edema control.

**Dr. Michlovitz:** Dr. Swartz, this patient is a woman who smokes about a pack and-a-half of cigarettes a day. Would you discuss this with her, would you expect that it would have any effect on her healing from this injury?

**Dr. Swartz:** These patients are recalcitrant. You are not going to change her smoking habits and as soon as she leaves the hospital she is going to do whatever she wants to do. Frankly, I don't think it will make any difference.

I do have some concern about the idea of early motion in this injury. The normal course of events is to have a rise and fall of edema after this injury. This edema can only be manipulated to a certain



**A HIGH IMPACT INJURY MAY BE ASSOCIATED WITH TFCC, SCAPHOLUNATE AND NEUROVASCULAR INJURIES.**

PAUL ZIDEL, MD

degree in the first five days. So I would not spend a lot of energy trying to get motion in that time period, but would rather pay a lot of attention to splinting and a protective position. While I don't use an I.V. pole to suspend arms, I do like the foam splint that keeps the hand elevated in a bed setting. It at least takes some control in those first five days with the MP joints flexed and the IP joints extended, and the wrist extended or neutral.

I don't have any problem with passive finger flexion, but if there is indeed a substantial soft tissue injury to the forearm, any motion of the finger extensors or finger flexors is going to be painful and could affect the skin graft take. I agree, after five days, motion can be started and the skin graft won't be affected. It is a big deal if you lose a skin graft and have a chronic granulating painful wound. I think you are going to lose some ground if you start moving this patient's extremity too soon. I would prefer beginning active motion after five days, provided she was protected in a position of function.

**Dr. Michlovitz:** So then you are recommending no instruction in active motion, but maybe gentle passive motion with elevation during that point in time?

**Dr. Swartz:** Correct.

**Dr. Michlovitz:** What would be your management if in five days the graft did not take?

**Dr. Swartz:** It would depend on how important is the soft tissue loss. Now you have set a different set of priorities. An open granulating wound is a major initiator of edema and fibrosis. My goal in the soft tissue management of this problem is to get as early wound healing as possible. I would possibly recommend immediate regrafting in order to get a closed wound so that we are not dealing with a chronic wound that is going to lead to additional stiffness and fibrosis.

**Dr. Michlovitz:** Okay, we will take the best case scenario that the graft did

take and from week one to about week four, what would be your management of this patient? Dr. Zidel?

**Dr. Zidel:** Basically I would continue edema control and gradually increase active and passive motion, as tolerated. When there is comminution of the fragments, if we can get early wrist motion so much the better. The concern about a comminuted intra-articular fracture would be the incongruity and depression of the fragments and associated cartilage. I would be concerned about trying to achieve better motion early, especially in the wrist. Also, there is the distal radioulnar joint fragment, which I believe was not addressed. That is important to address because of the risk for pronation/supination problems.

**Dr. Michlovitz:** Dr. Cohen, would your management be similar?

**Dr. Cohen:** Yes, but I would defer to Mr. Brach. I think that as physicians, we have performed the initial operation stabilizing the bone, and the soft tissue envelope has healed. Our therapists must now help us in terms of gaining motion and function, which of course is the ultimate goal.

**Dr. Michlovitz:** Mr. Brach, what would you do to maximize motion, particularly if you notice that the intrinsics were tightening?

**Mr. Brach:** I would start on active and passive range of motion into an intrinsic minus, or hook fist position, to help stretch the intrinsics. If there is significant tightness, I possibly would initiate dynamic or static progressive splinting, to provide a low load prolonged stretch to the intrinsic musculature. Tendon gliding exercises can be performed 10-15 times an hour along with blocking activities of the FDS and FDP.

**Dr. Michlovitz:** Dr. Zidel, you had mentioned that you would try to begin motion as soon as possible. When would you consider doing that?

**Dr. Zidel:** Even for a dorsal T-plate there is a fair degree of variability depending on the reduction and the stability of the reduction. If I felt there was stable, good, solid reduction and no other anticipated problems, I would start within the first week and-a-half to two weeks with protection under guidance and have her wear a splint between sessions

**Dr. Michlovitz:** Dr. Swartz would you do the same?

**Dr. Swartz:** I think what has been mentioned is appropriate. The difference between a solid T-plate with stable fragments and the comminuted fracture that is not very stable is dramatic. It's imperative to get union of the fracture. An unstable circumstance that is caused by too vigorous early motion is a step backward.

**Dr. Michlovitz:** Mr. Brach, if she is allowed motion at two to three weeks postoperatively, what type of motion would you have her do at her wrist?


**Mr. Brach:** Active and active assisted range of motion. No passive range of motion at this time.

**Dr. Michlovitz:** What would you use as a guideline as to dosage of exercise to know if you did too much or too little?

**Mr. Brach:** I would progress or cut back on the intensity of the exercise sessions based on her subjective reports of pain, particularly in the radial dorsal wrist.

**Dr. Michlovitz:** Dr. Cohen, do you have any guidelines as to what type of pain would indicate that perhaps

*continued on page 12*



**IF THERE IS INDEED A SUBSTANTIAL SOFT TISSUE INJURY TO THE FOREARM, ANY MOTION OF THE FINGER EXTENSORS OR FINGER FLEXORS IS GOING TO BE PAINFUL AND COULD AFFECT THE SKIN GRAFT TAKE.**

**WILLIAM SWARTZ, MD**



## AROUND THE TABLE

continued from page 11

motion was too much?

**Dr. Cohen:** Unfortunately, pain is subjective, and there is great variability with respect to pain tolerance. We typically have patients work on active wrist motion with interval splinting for comfort and support. They can remove the

splint for gradually increasing time periods, working within their level of discomfort. I'm still more concerned about finger motion than I am about wrist motion in this setting. It's nice to start the wrist early, but sometimes starting too soon can actually lead to a "flair" in swelling and pain. If she is doing adequately in terms of digital motion and as long as the initial fixation is secure, then I would begin progressive wrist mobilization within the limits of discomfort and swelling.

**Dr. Zidel:** May I make a comment before we proceed? Our information was that she a passenger and the driver was killed, so obviously there is

some emotional psychological issues that need to be addressed. These may reflect upon her progress.

**Dr. Michlovitz:** It was her boyfriend who was killed in the accident. She, I believe, received counseling and was very positive about her rehab, which isn't always the situation in an instance like this.

Now, if we can take her to the point where she has regained wrist

range of motion to about 30 degrees of flexion and 40 degrees of extension, she seems to have reduced extensor tendon gliding. This is limiting some of her wrist flexion, and also the skin is fairly adherent to the underlying tissue. Dr. Swartz, would there be some procedure you could do to help regain some wrist flexion?

**Dr. Swartz:** If the wrist flexion is indeed due to soft tissue adhesions, I think most of the wrist limitations are going to be in the wrist capsule. It would be unusual for the extensor tendons to be the limiting factor, but sometimes they are. If they are, the earliest that I would consider an extensor tenolysis would be at three months. Every time you add surgical trauma you go back a few steps in terms of new swelling, edema, and pain. Rarely is there a restriction in wrist motion from flexor tendon adhesions. When there is a dorsal T-plate, as in this patient, adhesions around the plate and in the extensor tendons is something to consider. Skin coverage would be an issue that should be addressed at the initial treatment phase. If the soft tissue injury was really more than appropriate for a skin graft, where restriction of tendon gliding might be an issue, one should consider initially providing a skin flap where fatty subcutaneous tissues would permit tendon gliding.

**Dr. Michlovitz:** As it turns out, she gained functional use of her hand and her wrist. And I think she was discharged about four to five months after the initial injury. Dr. Zidel, what measurement techniques would you use to determine final outcome?

**Dr. Zidel:** Basically there are the standard measurements of angulation, inclination, shortening, ROM, grip strength, etc. In addition there is patient satisfaction, whether they have been able to resume their normal activities, what are their pain levels, and whether their expectations were met. These are the emotional and functional criteria.

**Dr. Michlovitz:** Mr. Brach, I'm going to direct that same question to you because I know that you are in a practice that has multiple clinics and uses a significant number of outcome measures for your therapy patients.

**Mr. Brach:** My measurement technique to determine final outcome would be to ask the patients what they can do now compared to what they could not do at the initiation of therapy. More importantly, assessing their D.A.S.H. scores, which is an outcome measure that relates to the Disability of the Arm, Shoulder and Hand. I also administer the patient rated wrist evaluation, which was developed by Joy MacDermid, and was published in the April/June 1996 issue of the *Journal of Hand Therapy*. This is a functional questionnaire that deals specifically with the wrist. The scores from these questionnaires and the objective data all play a role in my decision-making process as to their outcome.

**Dr. Michlovitz:** When you use these measurements for outcome, you have probably done baseline measurements. At what point in time would you administer the D.A.S.H. or the patient rated wrist evaluation?

**Mr. Brach:** The D.A.S.H. is administered at the time of their initial evaluation. Our practice administers them once a week, although I think that may be too frequent. I think it would be more beneficial to administer them one to two months after the initial evaluation and then at discharge.

**Dr. Michlovitz:** Dr. Cohen, do you have experience in using either of those to measure outcome?

**Dr. Cohen:** We have used outcome tools for research purposes. In the office, we mainly use the standard measures of digital and wrist flexion, extension, forearm rotation and grip and pinch strength. Also, I think it's important to educate patients with wrist fractures with respect to expected recovery time.



THE D.A.S.H. IS ADMINISTERED AT THE TIME OF THEIR INITIAL EVALUATION, ONE TO TWO MONTHS AFTER THE INITIAL EVALUATION AND THEN AT DISCHARGE.

PAUL BRACH, PT

We try to explain at the initial office visit that while the majority of their function will return over the first three to four months, there continues to be improvement in terms of motion, strength and endurance for well over one year following these injuries. It is important that they understand from the start that there will be a long recovery phase with respect to reaching maximum improvement.

**Dr. Michlovitz:** I think it's also important for them to realize that just because their strength hasn't fully returned and their motion may not have fully returned, that that doesn't mean they will require supervised therapy for that extended period of time.

**Dr. Cohen:** Correct, or time off work.

**Dr. Michlovitz:** The reason why I wanted to discuss the second case is, at least from our perspective as therapists, very frequently we get a referral for therapy from a physician that just says "distal radius fracture". Often there isn't any other information provided to us, particularly in an outpatient setting. We know that certainly age, type of injury and bone stock have quite a bit to do with the management of a distal radius fracture.

The next example is that of a 72-year-old female who had a fall at home. She had an extra-articular fracture that was dorsally displaced. She also has osteoarthritis of her digits and she is accustomed to being fairly active. She is not pleased about the injury that she has. Dr. Cohen, what would you do with her when you first saw her?

**Dr. Cohen:** Again, I would take a history regarding major medical problems, hand dominance and general activity level. The latter is more important than chronological age. I would observe her skin, the deformity, vascular supply to the hand, and test sensation. If the fracture is displaced, a closed reduction with sedation followed by application of a splint would be next.

**Dr. Michlovitz:** And if the fracture

were unstable, what would you do?

**Dr. Cohen:** I don't think I would do anything different in the emergency room. The goal is to reduce the fracture as well as you can with one attempt and to immobilize the wrist. It is important to make sure that the splint ends appropriately in the palm to allow digital motion. Patients need to have adequate pain medication, and they need to be instructed to elevate the hand and begin motion of the fingers. This is especially true in someone who has underlying osteoarthritis. Treatment of the fracture is certainly not an emergency.

**Dr. Michlovitz:** At what point in time would you treat the fracture and what would you consider doing, Dr. Zidel?

**Dr. Zidel:** If the initial treatment in the emergency room does not provide an acceptable reduction, then you need to go up to the next step. I think it's important not to hyperflex the wrist excessively to try to establish a possible reduction. Then your treatment of choice, whether internal fixation or external fixation, will depend on the associated conditions and whether the bone stock needs to be augmented with a bone graft.

**Dr. Michlovitz:** If needed to be augmented with bone graft or with some type of bone substitute, Dr. Cohen, would the work that you have done in bone cement be applicable to this case?

**Dr. Cohen:** We really do not know where the bone cement will fit in our armamentarium in the treatment of distal radius fractures. If the fracture is reducible but unstable, one could certainly consider percutaneous pins, with or without an external fixator. If one needed to open the fracture, for example, to elevate articular fragments, often the subchondral bone requires support, especially in an osteopenic person. In that setting, the metaphyseal defect is typically filled with one's choice of graft material. The bone cement that you are refer-

ring to has the advantage of being injectable in paste form. It then hardens into a compound identical to the mineral phase of bone, with an ultimate strength equal to cancellous bone. It is FDA approved but not yet available on a widespread basis. Ultimately, we may use it to help fill metaphyseal defects following fracture. It is biocompatible and provides stability, which can allow a woman such as this start wrist motion and functional recovery more rapidly following injury.

**Dr. Michlovitz:** Dr. Swartz?

**Dr. Swartz:** I don't have anything to add to that. The type of injury you described is usually low-impact. There is not a comminuted fracture. So I would expect most of the time you would get away with a closed reduction and cast application for this problem. If it were unstable, then you may have to add some pins. I think that would be the extent that I would want to be involved in interfering with what otherwise can be a successful outcome.

**Dr. Michlovitz:** Mr. Brach, you are sent this patient for the first time after the cast comes off at eight weeks. How aggressive would you be in regaining motion of this woman's wrist and fingers?

**Mr. Brach:** Initially, not very. At her age of 72 she may have other conditions such as osteoporosis which is a contraindication for aggressive forms of treatment. I would perform grade 1 or grade 2 joint mobilizations to the wrist to improve



**WHEN PLACING THE EXTERNAL FIXATION DEVICES ON IN THE OPERATING ROOM, I THINK IT IS IMPORTANT TO METICULOUSLY PAD THE AREA BETWEEN THE BARS AND THE SKIN TO PROVIDE COMPRESSION WHICH WILL RESIST SWELLING.**

**MARK COHEN, MD**

## AROUND THE TABLE

*continued from page 13*

joint mobility and assist with pain. As time goes on I would intensify my therapy to her tolerance so as to maximize her function.

**Dr. Michlovitz:** Can you define for us what a grade 1 and 2 joint mobilization would be?

**Mr. Brach:** Grade 1 mobilizations are of small amplitude usually performed at the beginning of the range of motion, where grade 2 mobilizations are of a larger amplitude and are performed at the midrange of motion.

**Dr. Michlovitz:** For the physicians reading this you will see that our therapist referred to joint mobilization techniques by number grading. The higher the number grade the more vigorous the mobilization technique. If a patient returns with a lot of pain after therapy and you match a therapy note indicating

grade 3 or 4 mobilization, perhaps the motion was a little too aggressive.

**Dr. Zidel:** In a patient like this, once there is a reasonable reduction, and given her osteoarthritis and tendency for stiffness, would anyone use an indwelling pain catheter?

**Dr. Cohen:** For tenolysis type procedures, we sometimes place an indwelling pediatric feeding tube along the median or ulnar nerve for the administration of a long acting anesthetic agent.

**Dr. Zidel:** There are several companies who produce a regulated mechanism giving a constant flow drip of anesthetic like Marcaine.

**Dr. Swartz:** I have used a similar procedure for the treatment of flexor tenosynovitis to irrigate the flexor sheath. By adding some local anesthetic, early range of motion is very effectively achieved.

**Dr. Michlovitz:** If we can use a little bit different scenario that Dr. Zidel brought up. Let's say that this

woman had a fracture and the surgeon chose to use an external fixation device. What would your management be of that patient, Dr. Swartz, right after the external fixation device is put on? Would you send the patient home with instructions to exercise on her own or would you begin the new therapy within the first few days?

**Dr. Swartz:** I think that a lot of gentle tender-loving care is required for managing that patient successfully and I would probably use the expertise of the therapist much earlier than I would with the younger patient. I don't think I would instruct her to do very much on her own unless she happens to be extremely independent and strong willed. More often than not I think she would basically do nothing on her own. As a result, she would be left with a stiff hand.

**Dr. Michlovitz:** Mr. Brach, you would be the one, I suppose, that would help with the active control of the situation. What would you do with

# Plastic and Hand Associate

Dynamic plastic surgery practice with two physicians focusing on all areas of plastic surgery with a strong emphasis on hand surgery seeks BE/BC plastic surgeon. Ownership opportunity in two years. Hand fellowship or CAQSH required. Centrally located Midwest community, easy drive to Chicago or Indianapolis. New high-tech facility with OR, and hand therapy unit, plus experienced supportive staff. Motivated applicants please contact:

*Lain Ruch Downs,  
Practice Administrator  
at 219-523-1544  
or fax CV to 219-293-7933*



THE CENTRE, P.C.  
COMPREHENSIVE PLASTIC SURGERY

RiverPointe Medical Office Building  
500 Arcade Avenue, Suite 300, Elkhart, IN 46514

thecentrepc.com

Hand Surgery  
Quarterly

.....  
Summer  
2000



this patient?

**Mr. Brach:** Unfortunately, sometimes we see these patients after digital stiffness has set in. I prefer the patients be referred for therapy after their initial follow-up appointment with the physician. They can be instructed on digital range of motion and edema control while the external fixator is in place. Then we follow them on a weekly basis to make sure that there aren't any complications setting in. I think it is very important to do that right away to prevent complications.

**Dr. Michlovitz:** During the time an external fixation device is in place, what type of instructions do you give the patient in forearm rotation?

**Mr. Brach:** By holding their elbow at their side and rotating it gently using their own motion, with no passive force applied.

**Dr. Cohen:** May I go back just a second? When placing the external fixation devices on in the operating room, I think it is important to meticulously pad the area between the bars and the skin to provide compression which will resist swelling. We used to remove the operative dressing within a couple of days, but we now commonly wait five or seven days. That doesn't mean they don't begin finger motion immediately, but it is sometimes better to let the wound settle down a little bit before you start pin care and allow the skin to swell into the fixator.

The other thing we found helpful is the addition of a palmar splint. Although they have stable external fixation, adding a splint seems to make these patients much more comfortable. I'm not sure if there is micro motion at the pin-bone interface or if the splint simply provides a feeling of additional support.

In terms of supination and pronation, we tend not to encourage forearm rotation in the external

*continued on page 18*

## CODING CORNER

# CPT Coding for Hand and Finger Fractures

Stiles T. Jewett, Jr, MD, FACS

Little has changed in CPT coding of hand and finger fractures since the topic was last discussed in these pages approximately four years ago by Ray Janevicius (HSQ, Autumn, 1996). In that article Ray laid out a very concise and understandable approach to coding of these injuries. This column will review much of what was presented in that Coding Corner.

### Basics

Accurate coding requires description of the following:

1. Which bone?
2. Where is the fracture (shaft or intra-articular)?
3. What was done? – manipulation, closed or open reduction
4. What type of fixation was used?

– none, internal, external, percutaneous pins

CPT codes for hand and finger fractures are found from 26600 through 26765. Arthrodesis codes (occasionally utilized for complex fractures) are found in the 268XX series. Table 1 shows the progression across the top from left to right of simplest to most complex treatment. Anatomic location, from proximal to distal is depicted along the left margin from top to bottom.

It is important to note that CPT coding does not distinguish between fractures that are open or closed although the ICD-9 codes do. Also, the codes are not concerned with the specific type of fixation used—K-wires, rigid internal fixation, external fixation or no fixation.

### What is GLOBAL?

Basic fracture treatment codes include:

1. Local infiltration of medication(s) or contrast agents before, during, or at the conclusion of surgery.
2. Surgical approach, with neces-

*continued on page 16*

STILES T. JEWETT, JR., MD, FACS

TABLE 1

### CPT Codes

	Closed Treatment without Manipulation	Closed Treatment with Manipulation	Closed Reduction with Fixation	Percutaneous Pin Fixation	Open Reduction with or without Fixation
Metacarpal	26600	26605	26607	26608	26615
Bennett	26645-52	26645	26650	26650	26665
Phalangeal Shaft, Prox/Middle	26720	26725	26727	26727	26735
Intra-articular, MP/PIP/DIP	26740	26742	26746-52	26746-52	26746
Distal Phalanx	26750	26755	26756	26756	26765

Hand Surgery Quarterly

.....

Summer 2000

# CODING CORNER

*continued from page 15*

TABLE 2		
ICD-9-CM Codes		
	Closed	Open
Metacarpal Base	815.02	815.12
Metacarpal Shaft	815.03	815.13
Metacarpal Neck	815.04	815.14
Metacarpal - Multiple Sites	815.09	815.19
Bennett	815.01	815.11
Proximal Phalanx	816.01	816.11
Middle Phalanx	816.01	816.11
Distal Phalanx	816.02	816.12
Phalanx - Multiple Sites	816.03	816.13
Metacarpal and Phalanx Multiple Sites on Same Hand	817.0	817.1

- sary identification, isolation, and protection of anatomical structures, including hemostasis and nerve stimulation.
3. Placement and removal of surgical drains or suction devices.
  4. Closure of wound and repair of tissues divided for surgical exposure.
  5. Application of initial dressing, splint, cast, etc.

In addition to the above, complex fractures (the topic of this issue) usually require an open approach and fixation. The global service package for these CPT codes would also include, when indicated, the following:

6. Infiltration anesthesia.
7. Tenolysis and/or tenosynovectomy of tendon(s) required for surgical exposure.
8. Surgical dissection of nerve(s) necessary for exposure.
9. Exposure of the fracture.
10. Debridement of open fracture and wound.
11. Manipulation/reduction of frac-

- ture.
12. Insertion or application of internal or external fixation device(s).

The global service package does not include:

1. Supplies and medications.
2. Complicated wound closure requiring local or distant flap coverage and/or skin graft.
3. Regional Anesthesia.
4. Harvesting and insertion of bone graft (local or distant site).
5. Fasciotomy for documented compartment pressure syndrome or vascular abnormality.
6. Treatment of additional fractures and /or soft tissue injuries.

Note that if a **bone graft** is done as *part of an arthrodesis*, the CPT code *includes* the obtaining of the graft and the graft is *not* coded separately. If not specifically included, the bone graft *should be coded separately* (20900 - bone graft, any area; minor or small, e.g., dowel or button or 20902 - major or large).

ICD-9 Coding requires that you *name* the bone, give the location of the fracture and state whether the fracture was *open* or *closed*. ICD-9, unlike CPT, does not subclassify intra-articular fractures. See Table 2.

### You Code It!

A cold punch press operator suffers an open through and through injury of his left hand. X-rays reveal a significant loss of bony substance of the mid shaft of the third metacarpal. The wound is very contaminated with grease and metal shavings. At surgery, in addition to the fracture, an extensor communis tendon is repaired and, on the volar side of the palm, a profundus tendon and common digital nerve are repaired. Extensive debridement is required.

The operating microscope is used to repair the nerve (see last HSQ Coding Corner). Due to the loss of bone, a bone graft is taken from the iliac crest. Fixation is accomplished with multiple plates and screws. Because of soft tissue loss on the dorsum, a local flap is devised and mobilized to cover the defect. A gauntlet cast is applied.

### Solution:

- Adjacent tissue transfer 14040
- Repair common sensory nerve, hand 64834-51
- Repair flexor tendon, not in digital flexor tendon sheath 26350-51
- Debridement, skin, subcutaneous tissue, muscle, muscle fascia, and bone 11012-51
- Bone graft 20902-51
- Open Reduction of metacarpal fracture with fixation 26615-51
- Repair extensor tendon 26418-51
- Operating Microscope 69990

### ICD-9 Codes:

- Fracture, metacarpal shaft, open 815.13
- Laceration, extensor tendon 882.2
- Injury, digital nerve 955.6
- Fracture, metacarpal shaft, open 815.13

Good luck and good coding! H

# Healthier Than Ever Assets Offset Relatively Steady Expenses

For the year 1999, the American Association for Hand Surgery had total assets of \$727,539, which includes \$ 358,134 in cash and cash equivalents, \$286,445 in investments, \$79,322 in prepaid expenses and \$2,900 in accounts receivable. Total liabilities and equity include total deferred revenue of \$214,775, accrued liabilities of \$22,917 and total reserves of \$489,846.

Total Income for 1999 was \$561,182 and Total Expenses were \$548,639. This led to a Net Operating Profit of \$12,543. The Total Net Assets are healthier than they ever have been at \$489,847 (Table 1).

The four major sources of income to the Association come from 1) annual membership dues, 2) annual meeting income, 3) symposium and forum income, and 4) interest on our investments (Table 2). Income from dues continues to increase at a steady pace, indicating a steady membership number. Although the profit from the Hawaii Annual Meeting was marginal, it does reflect the positive trend of fiscal management and must be taken in light of the tremendous adjustments necessary over the past year with the introduction of our new administration.

The Annual Meeting continues to be the flagship of this society, and continues to increase in respect and reputation, both academically and socially. The Cumulative Trauma Disease Forum, co-sponsored by the American Association for Hand Surgery and the American Society for Surgery of the Hand, was felt to be a tremendous success as a joint venture by all involved, and generated a net profit to the Association of \$20,137. Our investments in the

ous years, due in part to a decision by the Board of Directors to reduce the number of annually updated published membership rosters. The *Hand Surgery Quarterly* remains an important venue for Association business as well as academic topics, and the Association owes a great debt of gratitude to Dr. James G. Hoehn who has served as editor for so many years. We also welcome Dr. Peter C. Amadio into this role as Dr. Hoehn retires from that posi-

	1994	1995	1996	1997	1998	1999
<b>Table 1</b>						
Total Income	311,200	576,700	533,300	611,894	499,991	561,182
Total Expenses	255,700	428,800	474,600	545,215	505,401	548,639
Net Income – profit (loss)	55,000	147,900	55,219	66,679	-5,410	12,543
Total Net Assets	203,333	351,261	406,480	473,159	467,749	489,847
<b>Table 2</b>						
Dues Income	222,448	227,875	223,890	222,041	220,400	236,831
Annual Meeting Income	*	237,596	220,596	249,817	207,385	232,864
Annual Meeting Net Income	*	37,240	46,480	20,315	-33,759	1,851
Investment Income	7,969	17,950	21,284	48,088	52,112	45,921
Forum Income	78,775	89,700	64,134	76,430	9,775	42,385
Net Forum Income	29,557	39,211	-14,164	17,561	-49,978	20,137
<b>Table 3</b>						
Publication Expenses	30,357	21,180	51,580	56,556	63,473	34,340
Annual Meeting Expenses	*	200,585	175,748	229,502	241,144	231,013
Forum Expenses	49,218	50,489	79,529	407,45	59,753	29,766
Committee Expenses		13,156	22,036	28,431	17,230	41,677
Relations	3,706	5,019	8,225	6,453	16,001	8,300
Management and Governance Expenses	142,348	138,379	137,474	137,838	135,000	141,185

First Chicago checking and money market accounts, the Schwab investment account and the T-bills continue to generate a respectable interest income at \$45,921.

Expenses for 1999 remained relatively steady, but do reflect changes in several areas (Table 3). Publication expenses have been reduced by nearly half from previ-

tion. Anne Behrens will continue as the Managing Editor, and we thank her for her continued fine efforts. We also welcome the development of the AAHS website ([www.handsurgery.org](http://www.handsurgery.org)) which promises to be a tremendous tool for the future activities of the



## TREASURER'S REPORT

*continued from page 17*

Association. Committee expenses have increased due to the increased allotment of research grants overseen by the Research Committee and contributions from the Hand Therapy Committee to the Vargas Award. Relations expenses remain steady, and include membership in the IFSSH by every member of the AAHS. The membership is well aware of the change in administration that the Association went through last year, with the formation of a new administrative alliance headed by Ms. Laura Downes Leeper, Executive Director, and the Illinois State Medical Society managerial services. This has resulted in a measurable improvement in the timeliness and completeness of our financial records, while preserving the outstanding contributions of our administrative staff to the daily activities of the Association, including the planning and implementation of our Annual Meeting and special courses. Expenses related to administration are up slightly, again reflecting the intense activity by Ms. Leeper and associates during this transition year. Governance expenses have been reduced substantially due to a revision of the Board of Directors mid-year meeting structure and venue.

We would like to thank Dr. Robert Schenck and his Board of Directors of the Hand Surgery Endowment. Their dedicated efforts have resulted in tremendous growth of the Endowment, which in turn has shown substantial financial support for the Annual Meeting through the Resident and Fellow Research competition, then

Poster Awards and the President's Invited Speaker. We encourage each and every member of the Association to continue his or her generous support of the Hand Surgery Endowment.

There is no doubt that our membership represents the lifeline of this organization. In order to see growth in our reputation as a leading voice in hand surgery providing advanced and reputable educational venues for Hand Surgery, we must grow in numbers. We encourage those non-members that have visited us at forums and our annual meetings to join our organization. We also encourage current members to seek out potential new members and encourage them to join. This certainly includes our international colleagues!

As we head into the new millennium, we are well set. Under the guidance of Dr. William F. Blair, our current president, and the Board of Directors, we are poised to offer the members of this fine Association a world of new opportunities related to hand surgery, and do so on sound financial footing. As a final note in this report, I would like to take the opportunity to thank my predecessor, Dr. Alan Freeland, who provided dedicated service to this Association as treasurer for the preceding three years. Now that I am in this role, I can fully appreciate the level of excellence that he demonstrated during his tenure, and I appreciate the mentoring that he provided to me as I prepared for this office. **H**

*Richard A. Berger, MD, PhD  
Treasurer, American Association for  
Hand Surgery*

## AROUND THE TABLE

*continued from page 15*

fixator. There is really no anatomic problem with forearm rotation, as the radius and hand rotate around the ulna. However, this sometimes places undue stress on the skin at the pin sites. Rotation, especially supination, seems to take several months to recover regardless of fracture treatment. I don't have any problem allowing patients to rotate to carry out their normal daily activities, but I don't think they need to push passive supination and pronation while their fixator is on.

**Dr. Michlovitz:** Does anybody else have anything to add to that?

**Dr. Zidel:** Regarding these outcome studies, in an ideal world I would love to have a database of patients, your x-rays, your treatment options, your outcome, and the patient's and surgeon's comments at the end, in terms of their satisfaction. So when you are faced with a somewhat delicate situation, it would be wonderful to say hey, let me look for this particular comminuted intra-articular fracture of a 72-year-old woman on chemotherapy and so on with no bone stock. I would be able to contact those surgeons who had similar patients and pick their brains. That's a wish.

**Dr. Michlovitz:** So you are interested in more uniform recording of some status of impairment and disability?

**Dr. Zidel:** Although, it's very difficult to get uniform recording, because it depends on so many variables, such as which plate was placed, when it was placed after one's injury, and so on, but the more information the better. That way, we can make more intelligent decisions.

**Dr. Michlovitz:** Okay. Thank you all for participating tonight. **H**


## ASP's

**J**ust when it seemed that every conceivable acronym in the computer world had been created, some of them are now being re-used! ASP is short for Active Server Pages—the Web-based programming language of Microsoft that permits Web sites and databases to communicate. More recently, however, the term has also been used to represent Application Service Providers. This emerging industry has attracted billions in investment with traditional heavyweights like IBM, Compaq, AOL and others weighing in ([www.ASPnews.com](http://www.ASPnews.com)). The ASP concept is an extension of the ISP (Internet Service Provider). ISP's connect you to the

Internet. In simple terms, their computer lets you establish a dial-up connection, and in turn, the host computer is on the Internet. The host computers (called servers) at the ISP also host Web sites. In a way, each Web site is a small application in and of itself. Two or three years ago, most Web sites only displayed information. The emergence of programming languages like Active Server Pages and Java permitted "Web pages" to do much more so that today, many Web sites approach true business-grade application specifications. Witness the transactions that flow through Dell and Schwab on a daily basis and one quickly sees e-commerce driving the trend to more and more functional Web development.

So what does the ASP (Application Service Provider) actually do? In a sense, the ASP is a

fancy ISP, hosting Web sites functioning as business applications. Real data and real financial transactions flow through the ASP placing premium demands on the technology "up time", disaster recovery capabilities, and data integrity. Application upgrades are instantaneous across the network, and costs are driven downward significantly by the ASP concept. In fact, many "in-the-know" people in the computer industry have predicted that most business and consumer software needs will come directly off the net in the not so distant future. Keep your finger on the pulse of this trend as innovative medical apps emerge on the Web this year. **H**



J. DANIEL LABS, MD

## 2001 Application for Research Grants

The AAHS Research Grant Awards were established to further the purpose of the Association as stated in its Bylaws and to foster creativity and innovation in basic and/or clinical research in all areas pertinent to hand surgery.

### Awards and Eligibility

Grants will be made for a one year period to up to three investigators. Grants are available to all AAHS members. One of the investigators must be an **active** or **affiliate** member of the association.

### Grant Application

Applications may be obtained from:  
 American Association for Hand Surgery  
 20 N. Michigan Avenue, Suite 700  
 Chicago, Illinois 60602

Applications (**an original plus seven copies**) must be received by the committee chair no later than **Wednesday, November 1, 2000**, in order for the judging to be completed in time and the recipients to be announced at the Annual Meeting.

The AAHS and the Research Committee are required by the IRS to document disbursement of grant funds. Award recipients will be required to sign a letter of acceptance and submit a progress report once each year. The AAHS must be acknowledged as the source of funding in any presentation or publication. A final report must be submitted at the completion of the study. It is expected that the results of the funded research be submitted for presentation at an Annual Meeting within two years of the receipt of the award.

Funds must be returned to the AAHS if the study is not undertaken within twelve months of the receipt of the award.

Failure to follow these guidelines will disqualify the recipient from any further grant opportunities and from presenting any papers at the AAHS Annual Meeting for a period of three years following such default.

### Mail Grant Proposals to

Saleh M. Shenaq, MD  
 Baylor College of Medicine  
 6560 Fannin Street, Suite 800  
 Houston, TX 77030



# American Association for Hand Surgery Calendar

## 2000

**July 15-16, 2000**  
Mid-Year Board of Directors  
Meeting  
Chicago, Illinois

## 2001

**January 10-13, 2001**  
31st Annual Meeting  
Loews Coronado Bay Resort  
San Diego, California

## 2002

**January 9-12, 2002**  
32nd Annual Meeting  
Westin Caesar Park  
Cancun, Mexico

## 2003

**January, 2003**  
33rd Annual Meeting  
Hyatt Regency, Kauai  
Kauai, Hawaii

For information contact:  
AAHS Central Office  
20 North Michigan Avenue, Suite 700  
Chicago, Illinois 60602  
Phone 312-236-3307  
Fax 312-782-0553  
[www.handsurgery.org](http://www.handsurgery.org)



**HAND SURGERY**  
QUARTERLY



[www.handsurgery.org](http://www.handsurgery.org)  
20 North Michigan, Suite 700  
Chicago, IL 60602

Bulk Rate  
U.S. Postage  
**PAID**  
Permit No. 1266  
Eau Claire, WI

## Inside This Issue:

- 1 *Endowment Sets Goals*
- 3 *Report from the President*
- 4 *Profiles: AAHS Directors at Large*
- 6 *Hand Therapy & Affiliate Member  
Corner: 1999 Vargas Report*
- 9 *Around the Hand Table: Fracture  
Management*
- 15 *Coding Corner*
- 17 *1999 Treasurer's Report*
- 19 *The Digital Hand Surgeon: ASPs*