

# HAND SURGERY

## QUARTERLY



## Panels, Papers and People Pack Meeting with Lively Punch

**F**or two days clouds and rain covered San Diego; but the silver lining was unprecedented participation in the 2001 meeting of the AAHS. Tee times were replaced by lively discussions in the general sessions, instructional courses, and panels. An international group of presenters and moderators delivered good science and an academic discourse. The instructional course lecturers were as fine a group of teachers as you'll find at any conference.

Panel presenters Peter Stern, MD and Scott Kozin, MD gave practical insights into deceptively difficult hand fractures. John Seiler, MD, John Taras, MD and Brian Adams, MD produced an A-Z panel on flexor tendon injuries. Susan MacKinnon, MD, Dean Sotereanos, MD and Alan Bishop, MD combined for a comprehensive panel on nerve injuries. Our first-ever resident and fellow's day was a success by virtue of strong open papers and a resident/fellow-run panel. Residents Peter Chiang, MD, Tom Hughes, MD and fellow, Mike Dunn, MD did an excellent job presenting the


*continued on page 5*

William Blair, MD  
introduces AAHS  
Presidential  
Invited Lecturer  
Joseph  
Buckwalter, MD.



Joint Day Program  
Presidents' Invited  
Lecturer Michael  
Wood, MD

William Blair, MD,  
AAHS President  
congratulates  
Mark Baratz, MD,  
Program Chair, on a  
successful meeting.




# Teamwork

*"Two are better than one because they have a good return for their labor. If either of them falls, the one will lift up his companion."*

— Ecclesiastes 4:9-10

"No man is an island"; "the whole is greater than the sum of its parts"; no matter how it is expressed, the concept that groups can achieve things that an equal number of individuals could not is deeply engrained in human experience. The most recent meeting of the AAHS is a potent example. Three related but independent organizations, the American



PETER C. AMADIO, MD

Association for Hand Surgery, the American Society for Reconstructive Microsurgery, and the American Society for Peripheral Nerve all met over the long weekend of January 11-16, 2001, in San Diego. Five hundred hand surgeons and hand therapists joined forces to share experiences, and to learn from each other. By pooling resources, aggregate costs were reduced, and attendees got the benefit of not one but three superb Presidential Invited Speakers.

The three organizations have different missions, and so have no reason to merge, yet they realize that they share many common members, and are working to therefore minimize the duplication of effort that would necessarily arise from independent national meetings. Next year, the 'three amigos' will reprise their act in Cancun, Mexico, adding some salsa to the mix, and hopefully closer ties with our NAFTA partner and neighbor, Mexico, as well. North America is

the only region of the world where the national hand societies have not formed a continental hand federation. We have an opportunity to move in that direction. AAHS has already taken a leadership role, and can extend that with outreach to our Mexican and Canadian cousins. Through AAHS, we also have an opportunity to keep hand therapists as an integral part of the mix. I hope that one day all the North American hand surgery and hand therapy related organizations (and I include those devoted to the shoulder and elbow) will see the wisdom of closer connections, and will agree to hold at least one joint meeting every few years, as is the custom elsewhere.

In the meantime, AAHS can and should continue to play a leadership role in keeping our community

**NORTH AMERICA IS THE ONLY REGION OF THE WORLD WHERE THE NATIONAL HAND SOCIETIES HAVE NOT FORMED A CONTINENTAL HAND FEDERATION. WE HAVE AN OPPORTUNITY TO MOVE IN THAT DIRECTION.**

close, by coordinating truly integrated joint meetings as in San Diego and Cancun, and by widening the circle of participants. The twenty-first century will see increasing globalization, in all aspects of our lives. That trend, begun in the sixteenth century, was derailed for much of the twentieth, a victim of the brutal wars that marked its first half. The train is

now back on track, and the benefits of global exchange are being reaped now by more people, and more nations, than ever. Over time, the power of networks and information sharing is unstoppable. The organizations that realize this, and act to enhance cooperation, will be the leaders in the century to come. By maintaining its focus on the goals of better sharing and cooperation among the entire hand surgery family, rather than on pedestrian ambitions of control or power, AAHS has an opportunity to become the linchpin American hand surgery organization of the twenty-first century. **H**



**President**

Robert T. Buchanan, MD

**Editor**

Peter C. Amadio, MD

**Executive Director**

Laura Downes Leeper, CAE

**Managing Editor**

Anne B. Behrens

*Hand Surgery Quarterly* is a publication of The American Association for Hand Surgery and is published strictly for the members of AAHS. This publication is designed as a forum for open discussion and debate among the AAHS membership. Opinions discussed are those of the authors or speakers and are not necessarily the position, posture or stance of the Association.

Copyright © 2001, The American Association for Hand Surgery. All rights reserved. No portion of this newsletter may be printed without express written permission from the publisher, 20 N. Michigan Avenue, Suite 700, Chicago, IL 60602, 312-236-3307.

# AAHS in Great Shape and Getting Better

The AAHS is in the best shape it has ever been, as I assume its Presidency. I commend the forward thinking officers, committee chairs and an incredibly productive Central Office staff for bringing us to this level of organization.

Several years ago Dr. Bill Swartz began the process of forward planning as part of a mid-year Board of Directors meeting. An outside party acted as facilitator giving us an objective viewpoint. Under his guidance we focused on what the AAHS represented and what it should be doing for its membership. This allowed us to establish short and long-term goals for the organization. Since that meeting we have incorporated your ideas and wishes into the plan through use of a membership survey last year. Like the recent Presidential Election, your voice does make a difference. The Board of Directors has further refined the plan at each board meeting under the recent leadership of Dr. Bill Blair. It is my intention to continue the effort to define the future direction and lead the AAHS to provide greater service to its members.

At about the same time, the leadership also recognized the importance of a sound financial policy. Part of the most recent change in office staff was an improvement of the financial structure of the organization. Since the time when our received income and incurred expenses did not coincide, our new staff advised that we strengthen accounting practices and personnel

to allow better management of the organization's moneys. These changes allowed us to be financially secure in meeting our expenses throughout the year and to establish a reserve for unforeseen circumstances. Once the reserve was established, the Treasurer, Finance Committee, and Board instituted a

IT IS MY INTENTION TO...  
 DEFINE THE FUTURE DIRECTION  
 AND LEAD THE AAHS TO PROVIDE  
 GREATER SERVICE TO  
 ITS MEMBERS.

responsible policy to invest it. The combination of these policies will allow the AAHS to remain on strong financial footing no matter

the state of the general economy.

As part of our reorganization, we realized that we needed a better structure in order to function more efficiently and accomplish the goals of the Forward Plan. Through the considerable efforts of a number of people, including Dr. Nash Naam, who headed the project, the board instituted a Procedure Manual this year. This is a collection of documents containing each committee's charges, their calendars, and information to help each implement its duties. Previously, each new committee chair was on his own to relearn the job, unless the past chair was nice enough to help guide him. Now that initiation is built into the manual. This will help the AAHS accomplish its goals faster and with less overlap of responsibilities. One of my goals this year is to get each board mem-



ROBERT T. BUCHANAN, MD

*continued on page 4*



## American Association for Hand Surgery 2001 Board of Directors

- President**  
Robert T. Buchanan, MD
- President-Elect**  
Alan E. Freeland, MD
- Vice President**  
Allen Van Beek, MD
- Secretary**  
Ronald Palmer, MD
- Treasurer**  
Richard Berger, MD
- Historian**  
Nicholas Vedder, MD
- Parliamentarian**  
Robert Walton, MD

- Past Presidents**  
William Blair, MD  
William Swartz, MD
- Directors at Large**  
Mark Baratz, MD  
Richard E. Brown, MD  
William Lineaweaver, MD  
A. Lee Osterman, MD
- Affiliate Directors**  
Lynn Bassini, MA, OTR, CHT  
Paul LaStayo, PT, PhD, CHT
- Executive Director (ex-officio)**  
Laura Downes Leeper, CAE

Hand Surgery Quarterly

.....

Spring 2001

## FROM THE PRESIDENT

*continued from page 3*

ber and committee chair familiar and comfortable with the concept of a manual that is passed from one person to the next. This should then become an integral part of the organizational structure.

The board also wants to return as much value to the membership as possible. As part of this we began a web site, [www.HandSurgery.org](http://www.HandSurgery.org). We have continually added resources to this site. It now contains the membership directory. We have, however, contracted to upgrade the directory to include more information regarding each member's special interests or expertise. Navigation will also be improved. We are splitting this information to a member's only database containing all information and to a scaled down database the general public can access to find a hand surgeon, therapist, or allied practitioner in their area. In order to encourage the public to use this feature, we must provide other content to draw them to the site. We have charged the Education and Primary Care Committees to produce general information on hand problems that would interest the public. Several other committees are developing CME opportunities on the site to provide an easier way to meet the new CME requirements of the licensing boards. Additionally, information about the AAHS and the Annual Meeting and Symposia is contained on the site. We hope to make registrations for these available on line soon. Abstract submission is already done on line. This was very well received and went smoothly last year. Other enhancements to make life easier are in the works.

Dr. Keith Brandt, chair of the Internet Applications Committee, and Dr. Dan Labs, chair of the New Technologies Committee will be

working very hard this year to develop other ways for all of us to use the internet and other technology in our practices and daily lives. My goal is to have the AAHS home page the default screen on every member's computer. From there each member or staff can easily do whatever is needed to manage the office or their personal lives. Things we want available would be links to all other organizations one might belong and means of purchasing or accessing whatever is needed to run or manage the office. The possibilities are endless. If anyone has an idea of what is needed, please contact either of these committees or me. We need your input.

No group lives in a vacuum. Because of this, I believe we must

be informed about what is happening in the political arena. Therefore, I have established a Governmental Relations Committee under Dr. Donald Wehmeyer. This committee is charged with identifying governmental actions or pending actions that affect us in our everyday practices of hand care. Once identified, we will notify you through the newsletter or via a new membership e-mail newsletter.

I am especially thankful for what has already been done and for the very able board and committees I have to continue the job. I look forward to another great year for the AAHS. Let me know your thoughts on how the AAHS can improve. Otherwise, I'll see you in Cancun next January. **H**

## AAHS 2001 NEW MEMBERS

### Active Membership

Mehdi Adham, MD  
*Oklahoma City, Oklahoma*

Dimitri Anastakis, MD  
*Toronto, Ontario, Canada*

Edward Athanasian, MD  
*New York, New York*

Alejandro Badia, MD  
*Miami, Florida*

Yoav Barnavon, MD  
*Hollywood, Florida*

Thomas Beird, MD  
*Saginaw, Michigan*

Daniel Birkbeck, MD  
*Holland, Michigan*

Robert Buckley, MD  
*Tupelo, Mississippi*

Geoffrey Buncke, MD  
*Santa Ana, California*

Tyson Cobb, MD  
*Mt. Vernon, Illinois*

E. Gene Deune, MD  
*Baltimore, Maryland*

Peter Galpin, MD  
*Kahului, Hawaii*

Gregg Goldstrohm, MD  
*Greensburg, Pennsylvania*

Mark Gonzalez, MD  
*Chicago, Illinois*

Max Gouverne, MD  
*Corpus Christi, Texas*

Amitava Gupta, MD  
*Louisville, Kentucky*

Alexander Majidian, MD  
*Sherman Oaks, California*

Andrew Markiewitz, MD  
*Little Rock, Arkansas*

Stephen Miller, MD  
*Miami, Florida*

Stephen Milner, MD  
*Springfield, Illinois*

Scott Oates, MD  
*Houston, Texas*

Jorge Orbay, MD  
*Miami, Florida*

Kevin Renfree, MD  
*Phoenix, Arizona*

Jay Shenaq, MD  
*Houston, Texas*

Maria Siemionow, MD  
*Cleveland, Ohio*

Robert Slater, MD  
*Sacramento, California*

Dean Sotereanos, MD  
*Pittsburgh, Pennsylvania*

Scott Steinmann, MD  
*Rochester, Minnesota*

Helen Tadjalli, MD  
*St. Louis, Missouri*

David Toivonen, MD  
*Appleton, Wisconsin*

Eric Wegener, MD  
*Jackson, Mississippi*

Bradon Wilhelmi, MD  
*Springfield, Illinois*

### Corresponding Membership

Jan Ragner-Haugstvedt, MD  
*Oslo, Norway*

Yasser Safoury, MD  
*Cairo, Egypt*

Michael Sauberier, MD  
*Ludwigshafen, Germany*

### Affiliate Membership

Paula Galauz, OT  
*Milwaukee, Wisconsin*

Arthur Nelson Ware, PT  
*Jackson, Mississippi*

*continued from page 1*

relative merits of open versus limited-open versus endoscopic carpal tunnel release.

Several residents won big on the Hand Surgery game show "Who wants to be a Hundredaire". This was a highlight, in large part, due to the "color commentary" provided by Lee Osterman, MD, Scott Kozin, MD, Dean Sotereanos, MD, and Brian Adams, MD. Special thanks to Association president Bill Blair, MD, keynote speaker Jody

Buckwalter and Association all-stars Krista Greco, Laura Downes-Leeper, CAE, and Mary Jo Harrold. If we missed you this year, make your reservations for Cancun in 2002; program chairman Miguel Saldana is a man with a mission!

See you in Mexico,

— Mark Baratz, MD



## AAHS 2001 Research Grant Award Winners

There were 6 grant applications submitted and the following applicants have been awarded the 2001 research grant award:

### Research Grant Group #1

David W. Mathis, MD  
J.A. Nazzal, MD  
Eirik R. Svennevik, MD  
Mark A. Randolph, MD  
W. P. Andrew Lee, MD

### Research Grant Group #2

Allen T. Bishop, MD  
Saichol Wongtrakul, MD

### Research Grant Group #3

Konstantino  
Papakonstantinou, MD  
Julia K. Terzis, MD, PhD  
Frank Liuzzi, MD



From left to right: David Chiu, MD, ASPN President, William Blair, MD, AAHS President, Michael Wood, MD, Invited Lecturer, and Saleh Shenaq, MD, ASRM President.



Golfers enjoy an afternoon of relaxation at the Steele Canyon Golf Course.



## "Bridging the Hemispheres"

### 32ND ANNUAL MEETING

It's never too early to start thinking about next year's annual meeting. The association will hold its 32nd annual meeting January 9-12 at the Hilton Beach and Golf Resort in sunny Cancún, Mexico. The Program Committee has developed a preliminary schedule of events that will allow for a combination of education and warm weather recreation.

Cancun offers a wealth of Mayan cultural legacies, including Tulum, Xel-Há, Xcaret, Chicken-Itz', and other appealing places like Cozumel and Isla Mujeres just an hour or less away.

### CALL FOR ABSTRACTS

As the time, technology and society move forward, so have we. The AAHS will be conducting their call for abstracts on-line. This system has proven to be a great benefit to all. On-line submission and rating enables the authors to send text and graphics in a variety of formats, preview their submissions, and receive instant confirmation that their abstracts were received. The deadline for abstract submissions is May 1, 2001. For further information or to submit your abstract, log onto the Internet and point your web browser to [www.handsurgery.org](http://www.handsurgery.org).



### HOTEL INFORMATION

The 31st Annual Meeting will be held at the Hilton Cancun Beach and Golf Resort. Situated at the tip of the Yucatán Peninsula, the resort covers 233 acres in the heart of Cancún's Zona Hotelera. Angled to take in panoramic views, all guest rooms and suite feature terraces or balconies for outdoor relaxation. The hotel adds an extra level of pampering at its Beach Club, 80 rooms housed in low-rise villas. The resort's seven cascading pools form a dazzling aquatic complex, highlighted by two whirlpools and a swim up bar. Other facilities include a full service fitness center, two lighted tennis courts, a scenic golf course and a water sports center.

Rates:  
 \$220.00 Ocean View Room  
 \$270.00 Royal Beach Club Room

Reservations can be made by calling the hotel directly 011 52 98 81 8000 or through the hotel's toll free reservation service 1-888-594-2483. Please be sure to mention you

are attending the AAHS Annual Meeting. Members are encouraged to make their reservations early.

In addition to the Hilton, rooms have been reserved at the Ritz-Carlton Cancun. Standing on over seven acres of the Yucatán Peninsula, this luxurious oceanfront property is finely decorated in marble, antiques and chandeliers. All rooms have private balconies providing guests a magnificent view of the ocean. The hotel's amenities provide comfort, entertainment and fine dining in addition to lighted tennis courts, fitness center and spa. The Ritz is located in close proximity to the Hilton.

Rates:  
 \$285.00 Deluxe Ocean View Room

Reservations can be made by calling the Ritz Carlton directly 011 52 98 81 0808. Please be sure to mention you are attending the AAHS Annual Meeting. **H**

# Endowment Update: New Man, Same Mission

The idea of an endowment for the AAHS was Dr. Robert Schenck's vision in 1995. He took the helm of the Endowment and has sailed from a concept to a quarter of a million-dollar reality. He has stepped aside from the Presidency of the Endowment but remains on the Board of Governors for invaluable support and council.

During my tenure I will hope to proceed with the Endowment goals for the future. It is through your generosity that these goals can be achieved. As the Endowment grows it will be able to support more and more of the scientific program of the annual meeting. During the annual meeting held in Coronado, California the following events were supported in part or totally by the Endowment.

The Therapy Specialty Day "Rheumatoid Arthritis and Osteoarthritis of the Hand and Wrist: Update" was in part underwritten to help defray expenses. In addition,

the Endowment provided scholarship money to pay for part of the registration of the therapists attending the seminar.

Dr. Joseph Buckwalter, the Presidential Invited Lecturer, addressed the meeting about the impact of advances in science and technology on surgery. \$3,500.00 went towards this endeavor.

At the Awards Luncheon on Friday January 12, 2001 several awards were supported by the Endowment. The best scientific essay, "Lunate Cortical Strain in Wedge Osteotomies of the Radius for the Treatment of Kienback's Disease" by Benjamin C. Kam, MD, Steven Topper, MD, Sean McLaughlin, PhD; Qi Liu, MS; Lorenzo Pacelli, MD received a \$500.00 first prize award. "Extension Block Pinning of Displaced Mallet Fractures" by Eric P. Hofmeister, MD; Michael T. Mazurek, MD; Khiem D. Dao, MD; Alexander Y. Shin MD; Allen T. Bishop, MD received a \$500.00 award for best clinical essay. There were two poster awards of \$200.00 each. "Anatomy of the Iterossei



President Miguel Saldana, MD, with outgoing President Robert Schenck, MD and Jules Shapiro, MD who sculpted the Hands and the Fibonacci Sequence presented to Dr. Schenck.

and Lumbricals Revisited" by Firas G. Eladoumikhachi, MD; Paula Lee Valkov, MD; John Thomas, MD; David Netscher, MD won the best anatomical poster award. "Volar A-1 Pulley Approach for Fixation of Avulsion Fractures of the Base of the Proximal Phalanx" by Kevin M. Kuhn, MD; Khiem D. Dao, MD; and Alexander Y. Shin, MD won for best clinical poster.

Miss Gail N. Groth was the 2001 Vargas Award recipient. She will be supported in part by the Endowment when she travels to Uganda this year. She was granted \$1,000.00 towards that very noble endeavor.


As you can see, in just a few years, your generosity has been able to support \$12,000.00 for the projects listed above. A very sincere

*continued on page 8*

Incoming President Miguel Saldana, MD (left), with outgoing President Robert Schenck, MD (center) and Jules Shapiro, MD, who sculpted the Hands and the Fibonacci Sequence presented to Dr. Schenck.

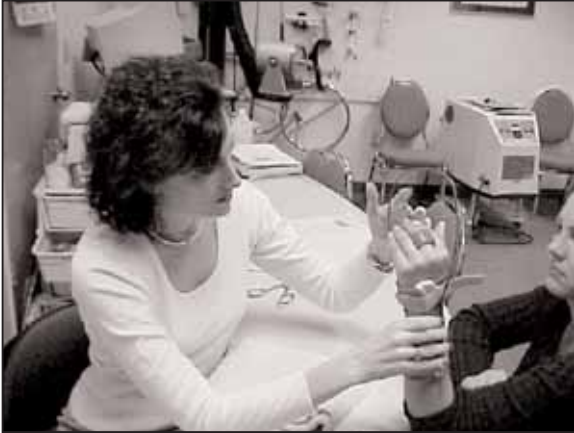

Dr. Saldana receives the Hand Surgery Endowment Presidential Clock from Dr. Schenck.



## Susan Weiss, OTR/L, CHT

**Personal:** I am engaged to a wonderful man who has two fantastic sons. Brandon is 9 and Justin is 6. I am most excited that when we marry, I won't have to change my occupational therapy license because we have the same last name. I live close to the water and enjoy boating with my friends and family.



### SUSAN WEISS, OTR/L, CHT

to help fund the research we are doing on splinting the first CMJ. Thank you! I attended the annual meeting in San Diego and learned all kinds of new goodies to take back to the clinic.

**Best Part of My Job:** The best part of my job is when a patient comes back after being discharged just to show me how great they are doing with their hand. I love when patients that have been discharged for years still send holiday cards with notes telling me how they are doing.

**Major Accomplishments:** I would say the most exciting of my accomplishments would be the publication of *Hand Rehabilitation a Quick Reference Guide and Review*, published in 1999 by Mosby; publication of "Prospective Analysis of Splinting the First Carpometacarpal Joint: An Objective, Subjective and Radiographic Assessment", by Hanley and Belfus in the *Journal of Hand Therapy*, June/July 2000; and teaching hand courses throughout the country. I am currently working on an exciting new accomplishment, but I'll save that for the next interview.

**Clinical Specialties:** My favorite things to treat in the clinic are traumatic injuries because they don't follow a cookbook recipe and they are usually very challenging. I also love to treat patients scheduling for reconstructive surgery, since I like to help them plan for the post op treatment regime.

**Greatest Challenge:** The greatest challenge I find in my practice is dealing with insurance companies. I find it very frustrating to not be able to see a patient that has an open wound or flexor tendon repair for an extra 4-5 days because of the insurance.

**Three Words That Describe Me:** Vivacious, enthusiastic, ambitious.

**H**

*continued from page 7*

thank you is owed to all of you who generously support the Endowment. Please continue to give towards this very worthy cause.

The Board of Governors of the Hand Surgery Endowment

Miguel J. Saldana, MD  
Joseph Danyo, MD  
Robert Walton, MD  
Robert R. Schenck, MD  
James Hoehn, MD

wishes to acknowledge the Resident/Fellows Award Committee

William Dzierzynski, MD, Chair  
Matt Concannon, MD  
Thomas Hunt, MD  
Douglas Rothkopt, MD  
Anthony Smith, MD  
Norman Weinzweig, MD  
Mark Wells, MD

and the Poster Award Committee

Kevin Yakuboff, MD  
Milton Armstrong, MD  
Glenn Carwell, MD  
Randi Galli, MD  
Lorraine Jensen, MD  
Mary Reuterfors,  
MA/OTR/CHT

for selecting the award winners for the Poster Awards and the Resident/Fellows Award at the 2001 Annual Meeting in San Diego, California.

*Miguel Saldana  
President, The Hand Surgery  
Endowment*

**H**



## “High Level” Therapy Specialty Day Filled a Void for Therapists and Physicians

by Paul LaStayo, PT, PhD, CHT

For years I have been hearing hand therapists: 1) bemoan the lack of “high-level” conferences and 2) pine for a course that would keep them stimulated from beginning to end. The Therapy Specialty Day at this year’s National Meeting in San Diego, dedicated to rheumatoid and osteoarthritis, seemed to fill that void. Coupled with the high level therapist and surgeon presentations were lively discussions that integrated the audience. With Adrian Flatt, MD, who made a surprise appearance, contributing greatly to the success of the day, all left the Therapy Specialty Day energized for the remainder of the week at the main AAHS meeting. When given the chance, we should all thank Sue Michlovitz, PhD, PT, CHT who orchestrated the entire event and culminated a stellar 2 years behind the scenes representing hand therapy as an AAHS Board of Director.

We also wish Gail Groth, OTR/L, CHT, MHS a bon voyage on her travels to Kampala, Uganda, with Scott Kozin, MD as this year’s Vargas International Hand Therapist Teaching Fellow. Named in honor of Miguel Vargas, MD this Fellowship provides \$4000 for a deserving hand therapist to travel with a hand surgeon and foster hand therapy and surgery in a host country. This program has been a tremendous success

and in Uganda, Gail will spend a rigorous two weeks in the region served by the Mulago Hospital. We look forward to hearing of her travels next year at the Cancun meeting.

At the 2002 AAHS Annual Meeting in Cancun, Mexico, we will see an exciting expansion of therapy-specific topics throughout the meeting. A hand therapist will be integrated into each instructional course and topic panel. We should also see several therapist scientific papers next year vying for the new \$500 award for the best paper. As always the Therapy Specialty Day will be integrative, informative and stimulating for both the “high-level” and neophyte therapist. Again like this year, the Therapy Specialty Day registration fee will be waived for affiliate members and applied to the registration fee for the main AAHS meeting. Although always strong advocates for hand therapists, the

AAHS is making an even greater effort to embrace hand therapy with the aforementioned fellowships, Therapy Specialty Day, instructional courses/panels, awards and discounts. The time is ripe for another recruiting effort with your colleagues. At \$75, affiliate membership has tremendous value. In fact, professionally it probably is the best \$75 one could ever spend!

Finally, I would like to extend a warm welcome to Lynn Bassini, OTR, CHT, who was elected by the Board of Directors as the Jr. Affiliate Chair, and Paul Brach, PT, CHT who will be heading up the Hand Therapy Committee this year. Both Lynn, Paul and myself look forward to an exciting year which will culminate in sunny Mexico next January. We hope you all feel the same and will come and join in on the fun in Cancun. **H**

The American Association  
for Hand Surgery  
would like to thank our  
5th Annual “Day at the Links”  
Golf Tournament Sponsors:

Avanta Orthopaedics

Cook Vascular

MCA

Med Link Medical, Inc.

Micrins Microsurgical Instruments, Inc.

Sensory Management, LLC

Wright Medical Technology, Inc.

Hand Surgery  
Quarterly

.....

Spring  
2001

# Rheumatoid Arthritis

At the 2001 Annual Meeting of the AAHS the morning topic of the Therapy Specialty Day seminar was rheumatoid arthritis. Some of the seminar participants have agreed to continue that discussion for the readership. They include: **Forst E. Brown, MD**, Emeritus Professor, Plastic Surgery, Dartmouth Medical School, **William F. Blair, MD**, Steindler Orthopaedic Clinic, Iowa City, IA, Past-President AAHS, **Nash Naam, MD**, Clinical Professor, Plastic Surgery Department, Southern Illinois University and Director, Southern Illinois Hand Center, Effingham, IL, **Jeanne Melvin, MS, OTR, FAOTA**, Clinical Director, Chronic Pain and Fibromyalgia Programs, Cedars-Sinai Medical Center, Los Angeles, CA, and **Katherine Anne Schofield, OTR/L, CHT**, Director of Hand Therapy, NovaCare Rehabilitation, Phoenix, AZ and Adjunct Professor, Midwestern University, Glendale, AZ. For an update on pharmacological management of the disease, turn to page 14.



**[ON] RESULTS FROM A DORSAL TENOSYNOVECTOMY... REPOIRTS SHOW... THAT ONLY ABOUT AN EIGHT TO TEN PERCENT RECURRENCE OF THE TENOSYNOVITIS AND ONLY ABOUT A FIVE TO TEN PERCENT TENDON RUPTURE.**

**FORST E. BROWN, MD**

**Dr. Brown:** Our approach tonight will be to present several patients with rheumatoid hand problems and consider their management. We will assume that the surgeon and the therapist are working closely together.

The first patient is a 48-year-old right-hand dominant woman who is referred because of uncomfortable synovial swelling of the MCP joints of her right dominant hand. This has not

responded to medical therapy. Joints show minimal subluxation, lateral instability on passive flexion, and an ulnar drift of 20 degrees. There is correctable swan-neck deformity of the PIP joints, except when the MCP joint is passively extended to neutral. The fingers can be flexed within 2 cm of the distal palmar crease. Thumb function is good with excellent lateral pitch. The wrist has limited, but pain-free motion.

Dr. Blair, is there any information you might need before treat-

ing this patient?

**Dr. Blair:** Does she describe any functional loss?

**Dr. Brown:** No. I think what you are alluding to is that we need to get a good functional history.

**Dr. Blair:** I am also thinking ahead to her probable natural history over the next few months to few years. If she has functional loss, this along with her swelling and pain would move me towards surgical intervention earlier rather than later.

**Ms. Schofield:** I agree with Dr. Blair as far as taking a look at her current functional status. If she is not identifying any specific issues that are going on with her life at the moment as far as loss of function of the affected hand, I would opt towards therapeutic intervention such as trial splinting before considering any kind of surgical intervention.

**Ms. Melvin:** Do her MCP joints have joint erosions?

**Dr. Brown:** We definitely need x-rays on her at this point to see what is going on, to see if there is any erosion of the MP joints.

**Ms. Melvin:** What is limiting her finger flexion? Is it a tendon limitation or is it swelling in the PIP

joints? Does she have any PIP synovitis?

**Dr. Brown:** We will assume she has no PIP synovitis. I think it is a general functional problem, restrictive motion of both the MCP and the PIP joints, along with the intrinsic tightness. Should we consider splinting because of that intrinsic tightness?

**Ms. Schofield:** Absolutely. I think it would definitely be worth a try. As to what type of splinting to utilize: I would try to position her MCP joints as close to neutral as possible and leave her IP joints free. So it serves as an avenue in which to exercise, to stretch the intrinsics as well as a splint for protection.

**Dr. Brown:** Would you use any dynamic pull on the PIP joints with the MCP joints extended?

**Ms. Schofield:** I would try static first. And then if you didn't get any improvement in active and passive potential of the PIP's then I would consider dynamic splinting.

**Dr. Brown:** Ms. Melvin, you said at the meeting that you had some luck with cool treatment for synovial swelling. Can you comment on that?

**Ms. Melvin:** Some patients with RA who cannot tolerate ice packs are responsive to cool (cold tap water)

dips. Effectiveness can be determined by an improvement in ROM, and this should be demonstrated in the clinic before recommending this technique. For this patient I would recommend starting with a trial of cold modalities four times a day to reduce inflammation and improve ROM. However, compliance with this regimen is difficult. The technique that I am particularly fond of now is having patients keep a container of water in the refrigerator big enough to put their hand and wrist in, like a plastic pitcher. She would dip her whole hand and wrist (if it is indicated) in this refrigerated water for roughly 30-60 seconds or until the hand is really cold, four times a day. Patients can tolerate this better than ice packs, it is more convenient and there is full surface contact. The effectiveness and ease of application increases compliance.

Also for this type of patient, joint protection training would be critical as it can actually be an extremely powerful tool for reducing pain and swelling in the MCP joints. The particular technique that is most effective is teaching patients to use the palms of their hands for bilateral prehension to grip things; thus avoiding strong grip while the MCP's are swollen. This technique eliminates all deforming forces on the MCP joints and strengthens the finger extensor muscles through active extension.

**Dr. Brown:** What about static splints at night to keep the wrist in neutral or ulnar deviation and the MCP joints in neutral or radial deviation?

**Ms. Schofield:** I would certainly utilize that. I try to really encourage night splinting on most of my rheumatoid patients, especially if their hand deformities are passive-correctable. So like you said, try-

ing to orient the wrist in a little bit of ulnar deviation, protecting that ECU so you have better balance distally at the MP joints. I have them wear that splint indefinitely. Most patients are pretty compliant with that if the splint is well made.

**Ms. Melvin:** If this patient had no PIP synovitis and the problem was restricted to the MCP joints, I would try daytime splinting with a dorsal MCP splint that would hold the MCP joints in neutral and block MCP motion with a palmar piece that goes under the proximal phalanges. And I would have them use that in a couple of different ways. I would either do a trial of daylong use to totally take all of the stress off the MP joints during function. If that caused strain to the PIP joints, I would then use the splint as a specific technique for stretching the intrinsic muscles, starting 1 hour a day and building to 4 hours. Then I would either consider using the MCP splint at night or using a splint that would protect the MP joints and the wrist at night.

**Dr. Brown:** Dr. Naam, would you consider joint injection with steroids?

**Dr. Naam:** Yes I would. But we need to consider two elements here: first, clinically how much has the patient been bothered by the swelling of the MCP joints? Second, what is the radiographic staging? With patients in stage I (in whom there is no radiographic or minimal radiographic findings) or stage II (in which there is just narrowing of the joint space and minimal joint erosion) local injection of steroids could be very helpful.

I use Celestone usually use 6 mg. I have had good experience with Celestone because it does not produce skin depigmentation and trophic changes that occur with local injection of steroids. I also

usually inject a long-acting local anesthetic like Marcaine. I leave the needle in place, then I inject the Celestone through that same needle

**Dr. Brown:** Have you found the injection of steroid reduces the swelling?

**Dr. Naam:** It does to a significant degree and I have been very pleased. That is usually the first line of treatment. Some of them (maybe 60-70 percent) have complete or partial improvement of their swelling for several months.

**Dr. Brown:** I did a quick search of literature and it looks like about 75 percent or so of people have a response that lasts up to three months, but you can only get a long-term result, like a year or more, in only about 20- 25 percent of patients.

**Ms. Schofield:** Would a repeat injection be indicated for this patient? If you got a three to four month benefit for the cortisone, would you do it again?

**Dr. Brown:** Yes, I would.

**Dr. Naam:** I would probably inject it two or three times. But if the patient is going to need an injection every 2 to 3 months, then this indicates that the degree of synovitis is significant enough to require something else be done.

**Dr. Brown:** Dr. Blair, let's go back to you. Suppose this patient does



**SOME PATIENTS WITH RA WHO CANNOT TOLERATE ICE PACKS ARE RESPONSIVE TO COOL (COLD TAP WATER) DIPS.**

**JEANNE MELVIN, MS, OTR**

## AROUND THE TABLE

continued from page 11

have some early erosive changes, but not too much narrowing of the joint. We know that there is reducible volar subluxation, swan-neck deformity, some instability and an ulnar drift of 20 degrees. If you wanted to consider surgery because the patient is starting to get functional problems in whatever they are doing, what might you consider in terms of procedures?

**Dr. Blair:** Then this patient is probably a pretty good candidate for a soft-tissue reconstruction procedure. The technical features of the reconstruction include, through a transverse approach, a synovectomy, centralization of the extensor tendons, and cross-intrinsic transfers moving the ulnar intrinsic tendon or the ulnar lateral band from index, long and ring fingers to the adjacent fingers. The procedure includes release of the abductor to the small finger, making sure that you don't get down too far volarly and release the flexor.

**Dr. Brown:** What about the collateral ligaments? They have obviously been stretched out from the synovitis.

**Dr. Blair:** The only collateral ligament in my opinion that needs reconstruction is the radial collateral ligament MCP joint of the index finger. There are two approaches that can be taken technically. One is to simply imbricate the ligament and that can be done by suture placement. It could also

be done by simply transecting the ligament, overlapping it and suturing it together.

The way that I most commonly use is the same method that would be used if one were doing an implant arthroplasty: a detachment of the radial collateral ligament from its origin from the side of the second metacarpal and then advancing it proximally on the metacarpal approximately 2 mm. It is then reattached to roughened bone through a drill hole.

**Dr. Brown:** Dr. Naam, would you reef the radial collateral ligament on the index and/or any of the others?

**Dr. Naam:** Mainly the index.

**Dr. Blair:** I might also, if there is a lot of laxity in the other MCP joints, do the same thing for them just to provide some extra support for the fingers, a buttress to work against.

**Dr. Brown:** In terms of synovectomy, do you think it is it has any effect and is it long lasting?

**Dr. Naam:** There have been some studies. I think Wood in 1989 reviewed his experience with patients who were treated with synovectomy and he found that if it is done in patients in stage I, II or III the results are encouraging. But there are some other studies that indicate that synovectomy does not have a long lasting effect. So really there is sort of a mixed bag of information available for us.

I found from my own experience that it really can help improve the functional use of the patient's hand; and also it may delay or even alleviate the need for arthroplasty, at least for several years.

**Dr. Brown:** That has been my experience also.

**Ms. Schofield:** Would this surgery also be of benefit more distally at the PIP's as far as minimizing further hyperextension posture because of the intrinsic tightness?

**Dr. Naam:** I think especially for this patient who has some element of intrinsic tightness. She would benefit from intrinsic release and cross-intrinsic transfer.

**Dr. Brown:** For the two therapists: anything additional we might consider in the postoperative care if this patient has had surgery on the MCP joints?

**Ms. Schofield:** I think it is important to watch and make sure that the intrinsics stay in a lengthened position by positioning the MCP joints in as close to neutral deviation and zero as possible, either with a low profile extensor dynamic or static splint. I would opt for some kind of low profile dynamic splint so that you get some guided motion of the MCP joints. I would recommend night splinting for up to six months in an intrinsic minus position.

**Ms. Melvin:** If you send this patient to therapy and the synovitis came down 50 percent and the intrinsic tightness became negative, would you still consider doing the surgery as described by Dr. Blair?

**Dr. Naam:** Yes I would.

**Dr. Blair:** I would probably wait just a little longer. I tend to use 30 degrees of ulnar drift as the threshold. People don't seem to be functionally much impaired at 20 degrees and they don't necessarily rapidly progress if their disease becomes somewhat quiescent. However, once they get to 30 degrees they describe increasing amounts of functional loss and they seem to start to progress. This is probably because the biomechanics at 30 degrees are becoming increasingly disturbed.

**Dr. Naam:** Ms. Melvin, in the San Diego meeting you alluded to the general care of a patient with rheumatoid arthritis. When the patient is being seen for the first time, what kind of approach do you use in your evaluation? What are the important points that can help us in our evaluation of the



MAKE SURE THAT THE INTRINSICS STAY IN A LENGTHENED POSITION BY POSITIONING THE MCP JOINTS IN AS CLOSE TO NEUTRAL DEVIATION AND ZERO AS POSSIBLE, EITHER WITH A LOW PROFILE EXTENSOR DYNAMIC OR STATIC SPLINT.

KATHERINE ANNE SCHOFIELD,  
OTR/L, CHT

Hand Surgery  
Quarterly

Spring  
2001

12

patient as a whole rather than just a deformed hand or a deformed finger?

**Ms. Melvin:** I would ask the patients, what are they doing to help themselves get well? What is their self-management plan for taking care of themselves now that they have rheumatoid arthritis? If they say to "I am taking my medications and resting" then they don't really have a very effective plan. They now have an illness that is pulling down their health. At this point of illness patients need to improve or expand their lifestyle behaviors to enhance their health.

Over the last 15 years there have been numerous studies documenting the effectiveness of aerobic exercise training on rheumatoid arthritis: reducing the level of inflammation, joint counts, and improving function and quality of life. So, I would talk to the patient

about the overall concept of how to self-manage rheumatoid arthritis: the benefits of exercise, stress management, conscious relaxation, joint protection, eating healthy and particularly getting restorative sleep.

Then I would give them guidance on how these things can impact on both their RA and their health. I would direct them to community resources for help in this area, particularly the Arthritis Foundation with its extensive patient education literature and free self-management booklets. It is helpful to give them the ordering sheet and talk to them about which booklets would be most helpful from the AF and how to locate exercise programs in the community. The AF has both pool and land-based exercise programs in conjunction with the YWCA's throughout America, so they are easily available. They also offer the

Arthritis Self-Help Courses that provide excellent self-management training at a cost of \$35.00.

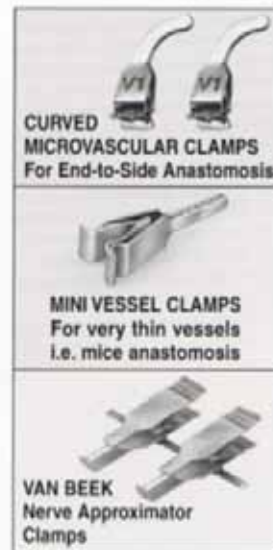**Dr. Blair:** Those are very important points. Could I pose one more difficult question? Is it our concept as hand surgeons and therapists that intrinsic transfer functions dynamically or statically? And based upon that concept, what are the implications then for post-op hand therapy?

**Dr. Naam:** I believe the transfer works primarily as a static element. What do you think?

**Dr. Blair:** I am not sure. I think practically it ends up functioning statically because the transfer probably adheres to the adjacent metacarpal capsule. However, it would be more ideal if it did to some extent function dynamically. I think if it is to function dynami-

*continued on page 15*

## ASSI®-your original and best independent source for Microsurgical Instruments...



...as well as a wide range of Cosmetic and Reconstructive Instruments.

**assi**  
ACCURATE SURGICAL & SCIENTIFIC INSTRUMENTS®

To do the best work, choose the best tools.™

accurate surgical & scientific instruments corporation

1.800.645.3569 (New York) 1.800.255.9378 (West Coast)

FAX: 1.516.997.4948 • E-MAIL: assi@accuratesurgical.com • INTERNET: www accuratesurgical.com


© 2001 ASSI®

Hand Surgery  
Quarterly

.....  
Spring  
2001

# Pharmacological Management of Rheumatoid Arthritis

*The Therapy Specialty Day seminar on arthritis at the recent AAHS Annual Meeting opened with an update on pharmacological management by LCDR Paul J. DeMarco, MD FACR, LCDR MC USN (Head, Division of Rheumatology, Naval Medical Center, San Diego.) He has agreed to answer, as a supplement to the "Around the Hand Table" discussion, several questions regarding arthritis medications.*



**METHOTREXATE... HAS THE HIGHEST COMPLIANCE RATE OF ANY OF THE DMARDS STUDIED PRIOR TO THE INTRODUCTION OF LEFLUNAMIDE, INFlixIMAB AND ETANERCEPT.**

**PAUL J. DEMARCO, MD FACR, LCDR MC USN**

## **What is the present role of Methotrexate in the management of rheumatoid arthritis?**

Methotrexate has emerged as the principal modality for the treatment of rheumatoid arthritis. It has the highest compliance rate of any of the DMARDs studied prior to the introduction of leflunamide, infliximab and etanercept. It is clearly the most cost-effective medication available and has a remarkably safe side-effect profile.

## **You mentioned in your San Diego presentation that Celebrex prescriptions are now in excess of those for**

**Viagra. This is an expensive drug. Are there advantages to its use as compared to other anti-inflammatory drugs?**

COX-2 agents have equivalent anti-inflammatory efficacy compared to available NSAIDs. The role of COX-2 agents revolves around the ability of these agents to decrease gastrointestinal toxicity

(i.e. ulcers and gastrointestinal hemorrhage) and to decrease bleeding risk. Patients at high risk for GI ulceration/bleeding and patients on anticoagulant therapy are appropriate candidates for the COX-2 agents. Patients at high risk for gastrointestinal toxicity from conventional NSAIDs include those with advanced age (> 76 yr. without other risk factors or > 65 yr. with other co morbidity), advanced disability, prior hx of NSAID-induced peptic ulcer disease, history of anti-ulcer medications, and corticosteroid use.

I believe these drugs are best used for the high-risk patients and patients chronically taking warfarin or heparin.

## **Would you comment on the use of Leflunamide and the TNF inhibitors in modifying the course of RA or even its remission.**

Leflunamide has been shown to modify the erosive disease of rheumatoid arthritis and clearly has a role in slowing the progression of erosive disease.

Etanercept (Enbrel) has been shown to slow progression of erosive disease and has been compared to methotrexate in this regard. In a recent *New England Journal of Medicine* study, the progression of erosion was slowed

more (statistically significant) at 6 months by etanercept than methotrexate. This statistical significance was lost at 12 months of study.

Similar information exists regarding infliximab (Remicade) with the exception that studies have suggested that erosions may "regress" with infliximab therapy. This was demonstrated by a decrease in the Sharp score during the study period. This score is designed to test the progression of disease, not regression. Suffice to say that this therapeutic is being watched closely for its remitting ability.

These three drugs are the first DMARDs available to demonstrate these Properties. I have been particularly struck by how well methotrexate performs when used aggressively in the "control" populations of these studies.

## **What are your recommendations on discontinuing drugs used to treat RA prior to surgery?**

I have contacted the pharmaceutical companies for recommendations and learned there are no guidelines. The following information is based on experience with pre-operative recommendations with methotrexate and *my personal* best guess based on the known pharmacology of these therapeutic agents.

Leflunamide has a tremendously long half-life; once reaching steady state in the blood and discontinued, the active metabolites can be detected in the blood for up to 2 years. Although it can be readily removed with cholestyramine (8 grams tid for 11 days), this is a difficult undertaking.

Infection risk is increased in these patients outside of the surgical state. I would treat these patients as those at risk for pros-

## AROUND THE TABLE

*continued from page 13*

thetic infections and provide a single dose of antistaphylococcal antibiotics prior to surgery and follow them closely in the outpatient setting with a low threshold for continued antibiotic therapy if post-operative infection is suspected.

Etanercept as a subcutaneous infusion is given twice a week. I would recommend stopping the therapy one dose prior to surgery. Schedule surgery 72 hours thereafter. I would restart as soon as possible, perhaps 72 hours after surgery in hopes to stave off a flare in rheumatoid arthritis.

Infliximab is given as an infusion once every eight weeks once the loading dose sequence is started (week 0, 2 and 6).

Clearly the immunosuppressive effects continue after each dose and likely decrease around the time of the next dose. I would recommend scheduling surgery 6-8 weeks after the last dose of infliximab and continuing to administer the infusion a week post-operatively.

Our experience with COX-2 agents has been to withhold only the dose on the morning of surgery. We have dosed the COX-2 agents the night before and after the surgery without bleeding complications. **H**

cally then the fingers have to move through the MCP joints as well as the PIP joints, at least to some extent fairly quickly after the surgery.

**Ms. Schofield:** So based on that comment then you would possibly employ dynamic splinting to allow protective MCP joint motion?

**Dr. Blair:** The way my thinking led me in later years was as follows. The static splinting that you describe, including the MCP joints in a neutral position with the PIP joints free is an excellent strategy and it is very helpful. Beginning at about seven to ten days post-op, when the pain and swelling were down, I started allowing patients to take the splints off and move all finger joints through a full range of motion, at least three times a day. And again, this is only my perception, but they seem to end up with better overall motion, no compromise in the correction of the ulnar drift. They seem to also have a little bit better finger dexterity with better abduction and adduction of the individual fingers for their activities of daily living.

**Ms. Melvin:** Are you describing patients with severe ulnar drift and subluxation requiring these procedures or just this patient in particular?

**Dr. Blair:** I was speaking in more general terms. However, the same principles would be applicable to the patient that we were talking about here with the lesser amount of ulnar drift.

**Dr. Brown:** I think I would summarize by saying that we would like it to be dynamic and do what therapy is necessary to achieve a dynamic pull on the radial side of the finger. Does that sound reasonable?

**Ms. Schofield:** Yes, it sounds reasonable.

**Ms. Melvin:** I haven't looked at post-op management in terms of the transfer being dynamic because the patients that I have treated following intrinsic transfers have had multiple severe problems that seem to dominate the post-op management more than considering the intrinsic transfer.

**Ms. Schofield:** Just getting back to mobilizing the MCP's. You centralize the extensor tendons. Are you worried if you have them flexed too much at the MCP joints that you will develop a significant lag?

**Dr. Blair:** I understand the concern. The risk in moving them is that the centralization will fail. You need at least three imbricating sutures, which places six suture strands across the radial side of the imbrication and that is a fairly strong repair. I suppose something one could do intraoperatively would be to perform the repair and then passively gently stretch the fingers down to 90 degrees to make sure that your centralizations held before you went ahead and moved them actively.

**Dr. Brown:** All right, let's go onto the second patient. This would be another female patient presenting with a non-painful synovial swelling of the dorsal wrist, present for eight months. Good medical therapy. No weakness of finger extension. Early carpal translation and supination are present. Distal



**IF MORE THAN 50 PERCENT OF THE LUNATE IS OUTSIDE THE LUNATE FOSSA OF THE DISTAL RADIUS, THEN I WOULD START TO BE CONCERNED.**

**NASH NAAM, MD**

Hand Surgery  
Quarterly

.....

Spring  
2001

*continued on page 16*

*continued from page 15*

## 2002 Application for Research Grants

The AAHS Research Grant Awards were established to further the purpose of the Association as stated in its Bylaws and to foster creativity and innovation in basic and/or clinical research in all areas pertinent to hand surgery.

### Awards and Eligibility

Grants will be made for a one year period to up to three investigators. Grants are available to all AAHS members. One of the investigators must be an **active** or **affiliate** member of the association.

### Grant Application

Applications may be obtained from:  
American Association for Hand Surgery  
20 N. Michigan Avenue, Suite 700  
Chicago, Illinois 60602

Applications (**an original plus seven copies**) must be received by the committee chair no later than **Thursday, November 1, 2001**, in order for the judging to be completed in time and the recipients to be announced at the Annual Meeting.

The AAHS and the Research Committee are required by the IRS to document disbursement of grant funds. Award recipients will be required to sign a letter of acceptance and submit a progress report once each year. The AAHS must be acknowledged as the source of funding in any presentation or publication. A final report must be submitted at the completion of the study. It is expected that the results of the funded research be submitted for presentation at an Annual Meeting within two years of the receipt of the award.

Funds must be returned to the AAHS if the study is not undertaken within twelve months of the receipt of the award.

Failure to follow these guidelines will disqualify the recipient from any further grant opportunities and from presenting any papers at the AAHS Annual Meeting for a period of three years following such default.

### Mail Grant Proposals to

Saleh M. Shenaq, MD  
Baylor College of Medicine  
6560 Fannin Street, Suite 800  
Houston, TX 77030



ulna is prominent dorsally and the ECU is subluxed volar. Additional studies? Dr. Naam?

**Dr. Naam:** Yes, this patient seems to have some element of extensor tenosynovitis of the wrist and I think the first thing we would like to do is to get an x-ray of the wrist itself. This would give us an idea of how much bone involvement there is, because this will have an impact on treatment.

I would also like to know where the distal ulna is going. Is it really actually subluxed significantly from the distal radio-ulnar joint or not and also to determine the degree of the ulnar translation. Probably there will be some involvement of the radio-lunate joint if there is some element of ulnar translation.

**Dr. Brown:** Right. Along that same line, when are you concerned about the ulnar translation of the lunate?

**Dr. Naam:** If more than 50 percent of the lunate is outside the lunate fossa of the distal radius, then I would start to be concerned. But it does not mean that you have to do something right away. If 70 percent of the lunate is outside the lunate fossa, then this is a significant degree of ulnar translation.

**Dr. Brown:** Dr. Blair, do you have any other comment on that?

**Dr. Blair:** Another helpful radiographic sign is widening of the radio-scaphoid articulation with the SL interval maintained. That is another good radiographic sign of significant ulnar translation.

**Dr. Brown:** What about flexion of the scaphoid?

**Dr. Blair:** Yes, either a D1SI or a V1SI pattern is of concern.

**Dr. Brown:** What about the tendons themselves in terms of trying to



figure out if there is synovial involvement?

**Dr. Naam:** Since there is no extensor weakness, it appears that the extensor tendons are at least not significantly involved. However, that does not mean that they are not involved to some degree. There have been some studies indicating that ultrasound could be helpful to identify the degree of infiltration of the tendons in addition to the clinical evaluation. That could be a useful study to study the status of the extensor tendons.

**Dr. Brown:** One of the clinical signs that I have found helpful is to watch the synovial swelling during flexion and extension of the fingers. If it moves, then that means to me that the synovium is adherent to the tendons and is probably invading them. If that is seen, then I would consider some additional studies like ultrasound or an MRI. Have either of you had any experience with these?

**Dr. Naam:** I have had experience with ultrasound, but usually I don't order an MRI in this particular situation. But I have had some patients who have had MRI for something else and it was also helpful to show the degree of infiltration. I believe that ultrasound would be more helpful if you were really looking primarily for infiltration of the tendons.

**Dr. Blair:** I haven't used either one and I suppose that part of the reason that I haven't is that I am not convinced or haven't seen evidence that tells me adherence or the lack of adherence decreases the patient's chance of rupturing the extensor tendons. To approach the issue differently, substantial extensor tenosynovitis in the presence of optimum medical management for three months or more becomes an increasingly strong indication to me to proceed with extensor tenosynovectomy and retinacular transfers to prevent extensor tendon rupture.

**Dr. Brown:** I think I would tend to be a little aggressive in these. It has been my experience and it is reported in the literature that about 50 percent of patients who have prophylactic tenosynovectomies do have tendon synovial invasion at the time of surgery. This is a major concern to me, because I think it is a lot easier to clean out a tendon than it is to repair it or perform a transfer.

**Dr. Blair:** But the converse may not be true. That is, in the absence of adherence or invasion, and even in the absence of bony erosion, the tendons can still rupture.

However, bony erosion is going to make it much more likely.

**Dr. Brown:** Of the patients I have seen who have tendon rupture, a good 95 percent or more have had either bony erosion of the tendon or synovial invasion of the tendon.

**Dr. Blair:** Well, I am not arguing that additional diagnostic study to get a clearer understanding of the path of physiology isn't reasonable. I think the argument I am developing is that I would use the general clinical presentation as an indication to be relatively aggressive about the synovectomies and retinacular transfer.

**Dr. Naam:** Let's ask both of you, how long would you wait on dorsal tenosynovitis before considering surgery? Do you immediately operate on them or do you wait a little bit? Do you inject them? Do you try other modalities before proceeding with surgical intervention?

**Dr. Blair:** I use three months or more of a moderate amount of extensor tenosynovitis in the presence of optimum medical management. I depend on my rheumatologists and trust them to optimize the patient's medical management. Then I track them for three months, and if it persists then I recommend surgery.

**Dr. Brown:** I use six months as a relative indication for surgery. I do not wait a significant period of time to get further diagnostic studies if there is any local pain, any weakness, if there has been tendon rupture on the other side, or if there is clinical evidence of adherence of the synovium to the tendon. Then I would get an ultrasound or an MRI to look at it, or consider surgery.

**Dr. Naam:** Any injections?

**Dr. Brown:** No.

**Ms. Schofield:** I have a question. In that six-month interim that you speak of, would you recommend prophylactic splinting to protect the tendons?

**Dr. Brown:** Yes I would. Why don't you comment on that.

**Ms. Schofield:** I certainly would as a preventive measure, especially since the ECU is subluxed volarly. One needs to try and protect that from further subluxation. Protecting the wrist with a splint during social activities during the day and then put on a resting splint at night is reasonable. Other issues, such as joint protection and general therapeutic management of the patient, would also be indicated.

**Ms. Melvin:** Since this patient did not have any MP involvement I would recommend a custom-made, rigid, wrist orthosis during the day to protect the ECU and reduce the stress to the dorsal compartment and possibly the same splint at night. However, if the MCP joints



**I VIRTUALLY NEVER FUSE BOTH THE MP AND IP JOINTS. IN THIS CASE OF A THUMB BOUTONNIERE DEFORMITY... I FUSE THE MCP JOINT AND THEN GO TO THE IP JOINT AND DO A CAPSULECTOMY.**

**WILLIAM BLAIR, MD**

The AAHS Board of Directors and the  
2001 Annual Meeting Program Committee  
would like to thank the following companies for  
their support and participation:

Acumed Instruments Corp.  
Ascension Orthopedics, Inc.  
ASSI, Accurate Surgical and Scientific  
Instruments Corp.  
Avanta Orthopaedics  
Biomet, Inc.  
Bionx Implants, Inc. Craniofacial  
Carl Zeiss, Inc.  
Cook Incorporated  
Cook Vascular Incorporated  
Cytometrics  
DePuy, a Johnson & Johnson Co.  
Designs for Vision, Inc.  
EBI  
FluoroScan Imaging Systems, Inc.  
George Tiemann & Co. Surgical Instruments  
Hand Innovations  
Hand Surgery Endowment  
Health Information Systems  
HTCC - Hand Therapy Certification  
Commission  
Jules Shapiro, MD - Sculptor  
KMI, Kinetikos Medical, Inc.  
Life-Like Laboratory  
Lippincott Williams & Wilkins  
Lone Star Medical Products  
MCA  
Med Link Medical, Inc.  
Medical Illustrations by Dr. Catherine  
Halinski  
Micrins, Microsurgical Inst., Inc.  
Microsurgery Instruments, Inc.  
Mitek Products  
Neurometrix, Inc.  
NeuroRegen, LLC  
Ortheon Medical  
OrthoLogic  
Orthopedic Systems, Inc.  
PMT Corporation  
Prescription Dispensing Laboratories  
Scanlan International, Inc.  
Sensory Management Services, LLC  
Sharpoint, Div. of Surgical Specialties Corp.  
Stryker Howmedica Osteonics  
SurgiTel/General Scientific Corporation  
Synthes USA  
TriMed, Inc.  
WB Saunders Company  
Wexler Surgical Supplies  
Wright Medical Technology, Inc.

## AROUND THE TABLE

*continued from page 17*

were involved that type of splint could aggravate them. So I would go to a more flexible splint during the day. I think you can get more control with a custom thermoplastic splint if you are actually trying to treat inflammation. I would also add cold modalities.

**Dr. Brown:** Let's assume we are going to do some sort of surgery. What would you do in terms of handling this patient's rheumatoid medications. Would you use antibiotics and how?

**Dr. Naam:** As Dr. Blair mentioned before, you have to have very good communication with the rheumatologists who are taking care of the patients. Usually ask them whether they prefer to stop the medications before surgery or not. Surprisingly I found that most of the rheumatologists now prefer not to stop any medications. I personally follow what the rheumatologist says. In general I don't stop any medications except in the patients who are on Coumadin. If patients are on aspirin or a nonsteroidal anti-inflammatory agent, I still operate on them while they are still on those medications. I do not use antibiotics.

**Dr. Blair:** I agree for the most part with Dr. Naam. I really don't change their rheumatoid medication regimen. As for antibiotics: I do pretty routinely use them, especially if I am going to be doing a procedure that is in a joint, or if there are any implants involved, or if the surgery is going to be two hours or more in duration. In this particular case, assuming that the surgery that I am envisioning is required, I probably would use prophylactic antibiotics, one dose pre-op for sure and perhaps two doses afterwards. I usually use a cephalosporin.

**Dr. Brown:** That's about the same thing I would do. How about a

local anesthetic in the wound before you make an incision?

There has been some suggestion that this does reduce the postoperative pain.

**Dr. Naam:** I personally use Marcaine at the end of the procedure but not at the beginning. I actually do that with every patient, with all kinds of surgeries that I do. That has been extremely helpful. I found that about 65 percent of our patients don't use any pain medications post-operatively. Are you aware of any studies that indicate that using antibiotics in those patients provide any different outcome? I have never had any patients in whom I used antibiotics pre-op for replacement arthroplasty and I don't recall having any infections in any of these patients.

**Dr. Brown:** I have not seen any studies. I think most people are basing their opinion on the orthopaedic studies on total joint replacement.

**Dr. Blair:** That is my understanding as well.

**Dr. Brown:** I use Marcaine both beforehand in the incision area and then at the end of the procedure.

**Dr. Blair:** I might comment on that too. I think that is a huge and very important change that we have made as we have moved to outpatient surgery in general. It really helps. As I am finishing the procedure I would anticipate using about 20 cc of 0.5 percent of bupivacaine. Before starting the closure I would inject even into the wrist joint. I would let the tourniquet down before the skin closure is done to make sure there is quality hemostasis and then after the closure I would inject the wound margins, usually from the inside out. Also whenever possible I come up the arm and do a specific nerve blocks. For example, in this patient, I would make it a point to block the superficial radial nerve at mid forearm level and the dorsal

branch of the ulnar nerve in the distal forearm.

**Dr. Brown:** Do you get the posterior interosseous nerve too?

**Dr. Blair:** Well, one should. That would be an excellent idea.

**Dr. Brown:** Do you drain the wound after a dorsal tenosynovectomy?

**Dr. Naam:** I personally do. I use a Jackson-Pratt drain and leave it for 72 hours.

**Dr. Blair:** For an inpatient I use the small rubber-band drains and usually run them out the ends of the incision for a long midline dorsal wrist incision. For some reason draining them centrally can be a problem. They often won't heal where that small rubber drain was. If they are outpatients, I don't drain them.

**Dr. Brown:** I use a small Penrose drain usually at the proximal or distal end of the incision. I agree with you that it is best to drain them from either end. Dr. Naam, what would you do to the distal ulna?

**Dr. Naam:** I probably would leave it alone at this stage because this patient does not seem to be symptomatic. She is not having significant ulnar wrist pain. It does not seem to be affecting her overall functions and there is no limitation of pronation or supination. However, for the subluxation of the ECU, I would probably proceed to try to relocate it using a slip from the extensor retinaculum or possibly I would do a transfer of ECRL to ECU. However, I think I would just do a relocation of the ECU.

**Ms. Schofield:** And why wouldn't you do that transfer, Dr. Naam?

**Dr. Naam:** The degree of ulnar translation is the determining factor. From the description of the patient's condition it appears that the ulnar translation is mild and

*continued on page 20*

## AROUND THE TABLE

*continued from page 19*

therefore has not been significant. So in that situation I would probably just relocate the ECU because the ECU itself would help stabilize and balance the wrist. If the patient has more ulnar translation, then you need to rebalance the wrist more actively or more dynamically by the tendon transfer.

**Dr. Blair:** In the circumstance that you have described, I probably wouldn't. It is a subjective call. If the patient were just a little bit worse, with some synovitis in the distal radial ulnar joint, the joint fairly lax and the ulna prominent or the radius somewhat volarly subluxed, I might address soft tissues. At a minimum I might open just the radial ulnar joint dorsally by making a longitudinal incision over the dorsum of the ulna, do a synovectomy, and if there was a rim of reactive bone, which there is in some of the rheumatoid patients, I might rongeur that away. I would then imbricate capsule as part of the closure, not doing much more than that.

Along with the extensor tenosynovectomy one would almost always do either a total or a split retinacular transfer. That transfer will exteriorize the ECU. It tends to bring it up just a little bit from its volar position. And I usually thought that that was adequate. As for constructing a specific sling to hold it further dorsally, I have always been a little bit skeptical about them, thinking that they probably weren't substantial enough to maintain that correction over time.

**Dr. Brown:** Just one further comment on what results we might obtain from a dorsal tenosynovectomy. There are several reports in the literature with up to five-year follow-up showing that only about an eight to ten percent recurrence of the tenosynovitis and only

about a five to ten percent tendon rupture. So it would seem to be from these follow-up studies that there is some benefit from a tenosynovectomy.

Let's go on to the third patient. This is going to be the same patient with some additional problems. There are now ruptured two extensor tendons: the extensor digiti minimi and the extensor communis to the small finger. There is more MCP subluxation. There is extensor tendon dislocation and ulnar drift to 60 degrees with good PIP motion; in other words, what we frequently see in our rheumatoid patients. If we assume she is not clinically able to handle the extensive surgery that might be indicated or if there is some contraindication to surgery, are there any additional splinting maneuvers that we might use?

**Ms. Schofield:** I think it is imperative that you splint to try to protect the remaining extensor tendons. Isn't it relatively common that once one ruptures, then usually another is soon to follow? I think it is important to try to splint them with the MCP's as near neutral as possible. The only trouble with that is they have a hard time functioning with that kind of splint, when their MCP's are tied up. So maybe positioning their MCP's in a little bit of flexion, supporting the wrist in a splint as well.

If they can handle that during functional tasks, then just having them use that and possibly looking at some sort of prefab splint which is a little easier for them to tolerate. It might be a better answer than a rigid splint. A dorsal splint is probably a little more functional because then the volar aspect is free for sensory feedback, but there are more bony prominences. I find that it is harder to get a good fit dorsally. What is your opinion on that?

**Ms. Melvin:** Usually patients with extensor tendon ruptures need to be protected until they go to surgery. We recommend a wrist

splint to reduce the attrition at the wrist level.

We don't include the MCP's. If there were concern about the little finger being in flexion, I would consider a buddy strap to the ring and middle fingers so the ring finger isn't pulled ulnarward. We then have the patient do range of motion exercises daily to make sure she doesn't develop an MCP flexion contracture. We always have to consider this is a bilateral disease. If you splint and limit function in one hand, how much stress is that going to put on the contralateral hand?

**Ms. Schofield:** Absolutely. That's a good point.

**Dr. Brown:** One of the reasons that I presented this patient is because I wanted to get into the subject of tourniquet time and staged procedures. Do you want to comment on that?

**Dr. Blair:** As we discussed at some length at the recent Therapy Specialty Day, I am an advocate of combined procedures as long as the postoperative rehabilitation isn't mutually exclusive for the given procedures, I don't believe that that would be the case in this clinical problem. So I would definitely do a one-staged reconstruction addressing both the MCP joints and correcting the finger deformities first, then transferring into the EDQM and extensor communis to the small finger as the second step.

As far as tourniquet time, again, there were a number of strategies and opinions presented at that meeting. However, as I approach the rheumatoid patient I extrapolate from my experience doing complex trauma with many hours of tourniquet time. We have used rolling two-hour tourniquet times (two hours up and 15 to 20 minutes down) and just kept right on going until the trauma case was done. This is based on practice and not upon any necessarily sound

*continued on page 22*

# ZIP!

As we all “go digital,” two technologies deserve attention. Knowledge of both is essential for file management with large, graphic-intensive presentations that are now pervasive at meetings.

First, Zip compression technology (<http://www.winzip.com>). Now in version 7, WinZip is an easy to use compression program for archiving large files. Many e-mail boxes limit storage to 10 Megabytes, and since graphical presentations can exceed this limit, compression will often solve transport issues. Zip archives are common, and therefore, the technology to manage these files is a must.

WinZip integrates with Windows 95/98/NT/2000, supports long file-names, drags and drops to or from the Explorer browser, and “zips” and “unzips” without leaving the browser.

Next, the Zip disc device (<http://www.iomega.com>). Without question, this is the cheapest and most widely used transportable large storage medium. The original version supported 100 Megabyte discs that look like a fat 1.44 standard diskette. Now, 250 Megabyte drives are available. CAUTION: a 250 drive can read 100 discs, but a 100 drive cannot handle 250 discs! Zip drives can be ordered internally with desktops and laptops alike and can also be purchased as an external drive. CAUTION: the external drives can, on occasion, be impossible to install on

Windows 95 and Windows 98 machines secondary to very difficult to define software problems!

Now on to a most important issue for presentations...


Like all computer drives, the zip disc requires a filing system before it can record information. Most typically, this is FAT or FAT32 (File Allocation Table; FAT32 supports smaller cluster sizes than FAT, which results in more efficient space allocation on

FAT32 drives). Now, with Windows NT and its new version, Windows 2000 Professional, NTFS is the preferred file system. This is an advanced system designed to support extremely large storage media and object-oriented applications. CAUTION: a computer reading FAT files will not necessarily “see” files recorded on an NTFS formatted disc. Here is the solution. If you are running NT or Windows 2000, check the zip disc format by right mouse clicking the drive letter in ‘My Computer’ and then selecting ‘Properties.’ The ‘General’ tab will display the file system that the drive is using. If your zip disc is NTFS, consider formatting the disc with FAT before copying your presentation to the disc and carrying the disc to a meeting:

Start/Settings/Control Panel/Administrative Tools/Computer Management/Disk Management/...then, highlight the zip drive letter, right mouse click, and format in FAT.

The same function can be accomplished from the DOS prompt. Formatting completely eliminates data files on the disc so make sure that the file is stored elsewhere. If the disc is already formatted in FAT, there is no need to repeat the process.

As we all migrate from traditional slides to Power Point for presentations, hard lessons will not elude us. Knowing your technology may save you from taking a “bye” at that crucial presentation. **H**



J. DANIEL LABS, MD

## Join a Winning Team

PeaceHealth Medical Group (PHMG) is looking for the best. We have strong programs and believe in providing a high quality of care. We are expanding to meet the need of a growing community and have opportunities available in Orthopedic Surgery. Eugene, Oregon, is a great place to live and PHMG is a progressive, innovative organization to work for with excellent salary and benefits. Contact us today! [llokey@peacehealth.org](mailto:llokey@peacehealth.org)



PeaceHealth  
Medical Group  
*Physicians and Surgeons*

## AROUND THE TABLE

*continued from page 20*

scientific basis. I have used two-hour tourniquet times, down for approximately 10 to 15 minutes and then back up for two hours, and doing it repetitively until the reconstruction is completed.

**Dr. Naam:** In making the decision to see what to do for this patient, we know that she has two problems at two different levels: wrist and MCP joints. At the level of the wrist I would agree with Dr. Blair that I would repair the extensor digitorum tendon of the little finger to that of the ring finger. I probably would also approach the distal ulna. If there are specific bony spicules of the distal ulna, these need to be removed by simple excision. However if the distal ulna is badly subluxed, then I would do a Darrach resection of the distal ulna. I would do both of these procedures at the same time with the replacement arthroplasty of the MCP joints. Since all of these procedures will require approximately 2.5 to 3 hours, I probably would leave the tourniquet on all the time.

If I feel that the procedure would need more time than that, I would agree with Dr. Blair that I would stop at two hours and leave the tourniquet deflated between 15 to 20 minutes, then come back and continue the procedure.

**Dr. Brown:** I lean the same way you do. If I can do something in 2.5 hours I will; otherwise I will let the tourniquet down and reapply it.

Just one quick comment on side-to-side tendon transfer: I had a mathematician show me that if you do a side-to-side transfer that it is impossible to get full extension of the finger whose tendon you are moving to the active one because of the angle between the side-to-side transfer and the pull on the good tendon.

**Dr. Blair:** I actually very much agree with what you and Dr. Naam said about the tourniquet time. In real life, if I can do the procedure in 2.5 hours or perhaps a little more, that is exactly the way I do it. But if it is going to be an extended, complex reconstruction that might run five or six hours, then I drop into the two-hour protocol.

**Dr. Brown:** Let me just ask a question on the fourth patient. Dr. Blair, she has a boutonniere deformity of the thumb with hyperextension of the IP joint. There is bone erosion in both joints. There is a functional FPL tendon. Would you tend to fuse both the MCP and IP joints or would you consider doing an arthroplasty of the MCP joint and a fusion of the IP joint?

**Dr. Blair:** Usually when you see that deformity the FPL is ruptured. I virtually never fuse both the MP and IP joints. The reason is that the thumb then functions as a unit with all extrinsics and intrinsics causing rotation through the CMC joint. It is not a thumb that is as functional as it could be, prehension is difficult, and I think it may well put the patient at risk for increasing problems at the CMC joint at a later date.

In this case of a thumb boutonniere deformity, even though there are erosions at the IP joint level (and this isn't certainly a published approach to taking care of the problem), I fuse the MCP joint and then go to the IP joint and do a capsulectomy. I bring the joint into flexion of about 30 degrees, even if it requires a conjoined tendon release and then I pin it there for about three weeks. I remove the pin and have the patient start working on active and passive range of motion from zero to 45 degrees.

Surprisingly, at least in my experience, those patients do relatively well, often having a pain-free IP joint and having, longer term, approximately 20 degrees of motion. They also retain good FPL

pull through to the tip of their finger, enhancing prehension.

**Dr. Brown:** Ms. Melvin or Ms. Schofield, any comments on therapy that you might use after a procedure like he described?

**Ms. Schofield:** I think you need to protect the fusion site with static splinting. (I have actually never seen the IP joints done that way.) In addition to protecting the IP joint, it is important to look at function of the thumb and how much stress goes through the thumb when they are doing daily activities. And again, joint protection comes into play and really trying to strengthen the thenar musculature and the first dorsal interosseous so they get a good lateral pinch. Taking a critical look at what they do and recommending various types of adaptive equipment is essential so as to minimize stress on the thumb on a long-term basis.

**Dr. Brown:** Would you use a hand-based splint to protect the MCP joint while you are allowing IP motion?

**Ms. Schofield:** Yes, if the fusion site is not healed. I would probably recommend using that for at least eight weeks post-operatively. Once the fusion site is healed, I don't think that is really indicated long term.

**Dr. Brown:** Any other comments?

**Ms. Melvin:** I would like to address this case from the standpoint of what to do with this patient if she were unable to tolerate surgery for some reason. If she were not a candidate for surgery, I would make a MCP immobilization splint, that is sort of a strip splint (1/16" Aquaplast) that starts over the dorsum of the CMC joint, wraps around the MCP joint, crossing over the dorsum of the joint with the end over the abductor pollicis brevis. It prevents motion of the MCP joint.

And I would have the patient wear this not only to reduce pain

## LETTER TO THE EDITOR

in the MCP and stabilize it, but to alter the flexion forces on the IP joint. In my experience if you have a stiff joint fixed in hyperextension of the thumb, you block MCP motion. The change in dynamics can actually bring the IP joint into flexion assuming it is a soft tissue contracture. Even 20 degrees of flexion at the IP joint, would help the patient's overall ability to function. If necessary, a figure-eight splint over the IP joint could be used to prevent it from hyper extending but still allow pinch.

**Ms. Schofield:** How much motion do you get typically after a thumb MCP arthroplasty? I have actually never seen one of those clinically.

**Dr. Brown:** About ten to forty degrees.

**Ms. Schofield:** And they are usually stable?

**Dr. Brown:** You really have to work on the ulnar collateral ligament.

**Dr. Naam:** This is exactly how I manage these patients. With the MCP joint arthroplasty, they won't have that much range of motion at the end and I am afraid that they may not be very stable. But the approach that Dr. Blair mentioned is excellent and probably in my opinion would be the best way to handle this situation.

**Dr. Brown:** I agree as long as there is not significant bony damage. I think that is the best way to go.

That's it for this evening. Thank you all for participating. **H**

*As Editor, my goal is to make HSQ as responsive as possible to its readers. When the occasion arises, we will publish letters which comment on features in past issues. Our 'Around the Hand Table' issue on cumulative trauma [HSQ AUTUMN 2000] elicited several responses from our readers, one of which is published below. We will certainly consider Dr. Stark's suggestion for future "Table" topics, and welcome each of you to comment on those features that are important to you. I cannot promise to publish every letter, but I can promise that I will give each my close attention. If there is enough correspondence on both sides of an issue, we may even be able to include an occasional "Readers' Forum" on topics of special interest.*

—Ed.

Dear Dr. Amadio:

I read with interest your panel discussion on cumulative trauma disorders [AROUND THE HAND TABLE, Autumn 2000]. In general, I found it very interesting and agreed with most of the comments made.

Near the end of the discussion, a digression into the relative merits of endoscopic carpal tunnel surgery was engaged in. Unfortunately, the panel was unbalanced in relationship to their view points and experience with endoscopic carpal tunnel surgery. Therefore, the inexperienced reader was left with the impression that, clearly, endoscopic carpal tunnel surgery was a bad and reckless technique based upon the consensus of all these experts.

I recognize that this is an area of controversy in the field of Hand Surgery. However, many reputable and experienced surgeons are utilizing the endoscopic technique safely and effectively. I have personally performed well over one thousand endoscopic carpal tunnel surgeries with the Agee device without major complication since 1991. I have carefully analyzed my results compared to the open technique. There is no question that in my practice and in my hands, it is a safe and superior technique for selected patients with carpal tunnel syndrome.

I hope a future discussion might be held with a balanced panel of experts to discuss the pros and cons of endoscopic carpal tunnel release specifically. I think it would be interesting, controversial and informative.

Sincerely yours,

Ron H. Stark, MD, FACS

*Milwaukee Hand Specialists, S.C.*

*Wauwatosa, Wisconsin*

# American Association for Hand Surgery Calendar

## 2002

**January 9-12, 2002**  
32nd Annual Meeting  
Hilton Cancun Beach & Golf  
Resort  
Cancun, Mexico

## 2003

**January 8-11, 2003**  
33rd Annual Meeting  
Hyatt Regency Kauai  
Koloa, Kauai, Hawaii

## 2004

**January 14-17, 2004**  
34th Annual Meeting  
Westin Mission Hills  
Palm Springs, California

## 2005

**January 12-15, 2005**  
35th Annual Meeting  
Sanibel Harbor Resort  
Sanibel Island, Florida

## 2006

**January 11-14, 2006**  
36th Annual Meeting  
Loews Ventana Canyon Resort  
Tucson, Arizona

For information contact:  
AAHS Central Office  
20 North Michigan Avenue, Suite 700  
Chicago, Illinois 60602  
Phone 312-236-3307  
Fax 312-782-0553  
[www.handsurgery.org](http://www.handsurgery.org)

**HAND SURGERY**  
QUARTERLY



[www.handsurgery.org](http://www.handsurgery.org)  
20 North Michigan, Suite 700  
Chicago, IL 60602

Bulk Rate  
U.S. Postage  
**PAID**  
Permit No. 1266  
Eau Claire, WI

## Inside This Issue:

- 1 *Annual Meeting 2001 Wrap Up*
- 3 *From the President*
- 5 *2001 Research Grant Award Winners*
- 6 *Bridging the Hemispheres: Meeting 2002*
- 7 *Endowment Update*
- 9 *Hand Therapy and Affiliate Member Corner*
- 10 *Around the Hand Table: Rheumatoid Arthritis*
- 21 *The Digital Hand Surgeon*
- 23 *Letter to the Editor*